

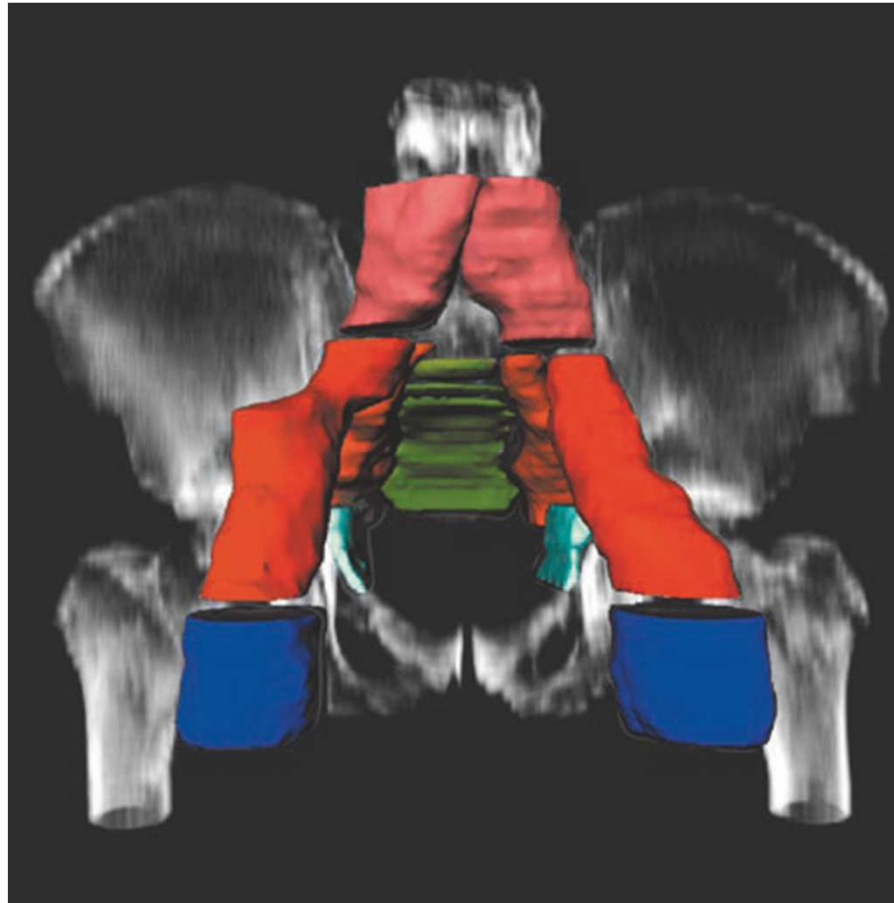
Pelvic & Inguinal lymph nodes



Dr. Firuza Patel

Professor,
Dept of Radiotherapy & Oncology
PGIMER,
Chandigarh

Pelvic & Inguinal lymph nodes



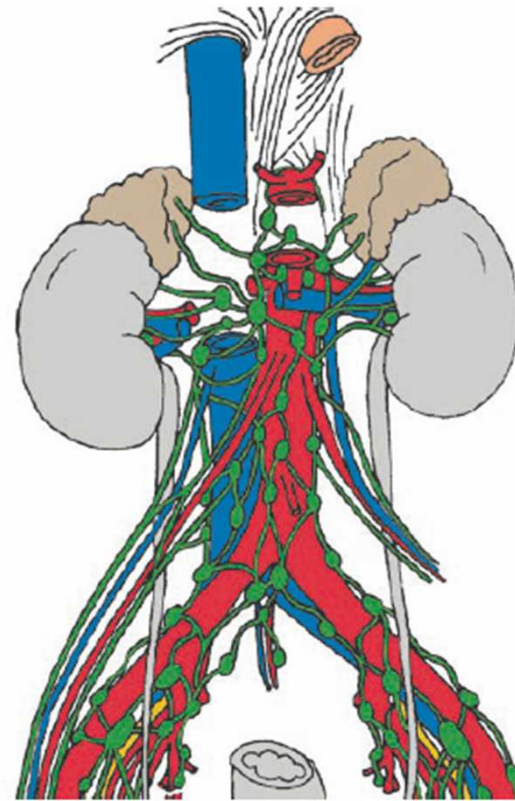
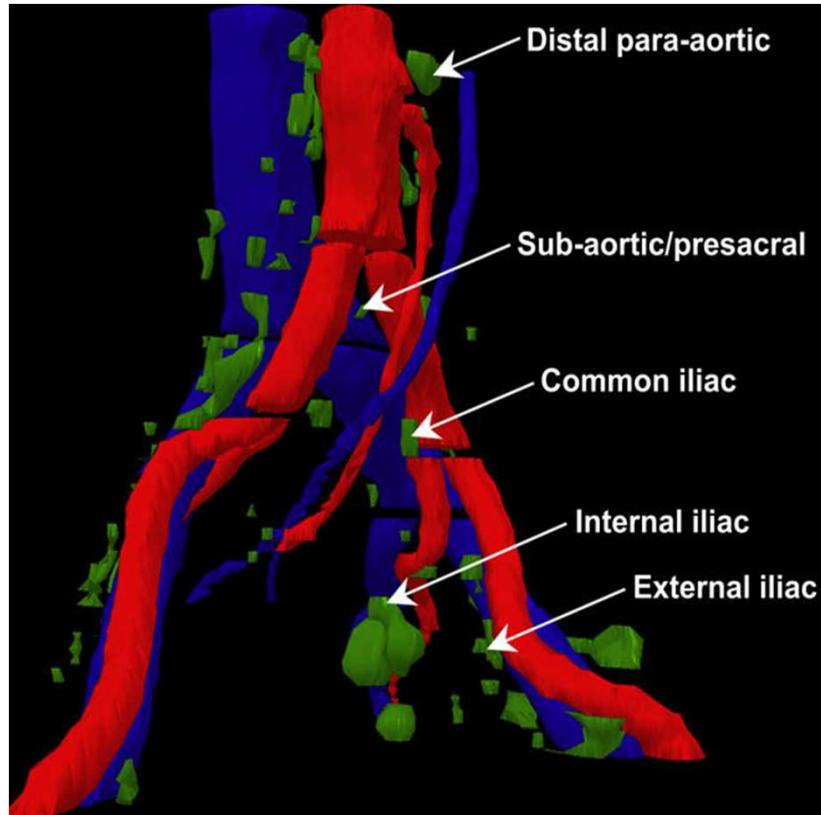
Pelvic & Inguinal lymph nodes

- ❑ The lymphatic system is a prominent route of spread for many malignancies.
- ❑ Therefore, radiation treatment of apparently normal lymph nodes is often advocated as a means of improving local disease control and improving survival
- ❑ Current imaging techniques are limited in their ability to reliably detect micrometastases in lymph nodes.

Pelvic & Inguinal lymph nodes

- ❑ Contouring of the clinical target volume of regional lymph nodes requires thorough understanding of two areas
 - ❑ **Distribution patterns of microscopic metastases**
 - ❑ **Anatomic features on cross-sectional images.**
- ❑ Lack of a standardized contouring protocol may result in considerable variation in lymph node coverage.

Lymph nodes along principal vessels



Pelvic lymph nodes lie adjacent to the major pelvic blood vessels and can, with an appropriate margin, be used as a surrogate target for lymph nodes

Pelvic & Inguinal lymph nodes

- ❑ Lymph nodes lie adjacent to the major pelvic blood vessels in the distal para-aortic, common iliac, and external iliac regions
- ❑ However, nodal tissue in the subaortic/presacral and obturator regions are found at greater distance from the major arteries and veins.
- ❑ These nodes are associated with smaller branches of the iliac vessels that are too small to be visualized reliably by using imaging.
- ❑ Therefore it is necessary to incorporate bony landmarks

Signs of Nodal involvement

- ❑ If a node is larger than 8 mm in short axis diameter in the pelvis or larger than 10 mm in the abdomen, it should be considered suspicious for metastasis.
- ❑ If the shape is round or irregular, the node is more likely metastatic.
- ❑ Signal intensity heterogeneity on T2-weighted MR images or central necrosis on CT images, is an additional potential evidence for metastasis
- ❑ Therefore it seems prudent to use a combination of **size, shape, and internal architecture** criteria together to consider a node as involved.

Pelvic Lymph Nodes

Anatomical description

- ❑ **Pelvic lymph nodes :**
- ❑ **Parietal lymphatics**
 - ❑ Superficial parietal
 - ❑ Deep parietal
- ❑ **Visceral lymphatics**
 - ❑ First located close to the viscera,
 - ❑ Then around the vascular pedicles of each organ
 - ❑ And then finally along the large iliac vessels

Pelvic Lymph Nodes

Anatomical description

❑ **Parietal lymphatics**

- ❑ **Superficial parietal** (present on the pelvic floor)
- ❑ Drainage of pelvic wall and all the soft tissues of the perineum below the outer fascial sheath of the urogenital diaphragm including **distal part of vagina below the hymen & inferior part of the anal canal below the ano-cutaneous line**
- ❑ Joins superior-medial group of **superficial inguinal nodes**

Pelvic Lymph Nodes

Anatomical description

- ❑ **Parietal lymphatics**

- ❑ **Deep parietal**

- ❑ Follow the parietal branches of the internal & external iliac vessels & make their first relay in

- Deep inferior epigastric – external iliac nodes

- Deep circumflex – external iliac nodes

- Sacral – internal iliac & sub-aortic nodes

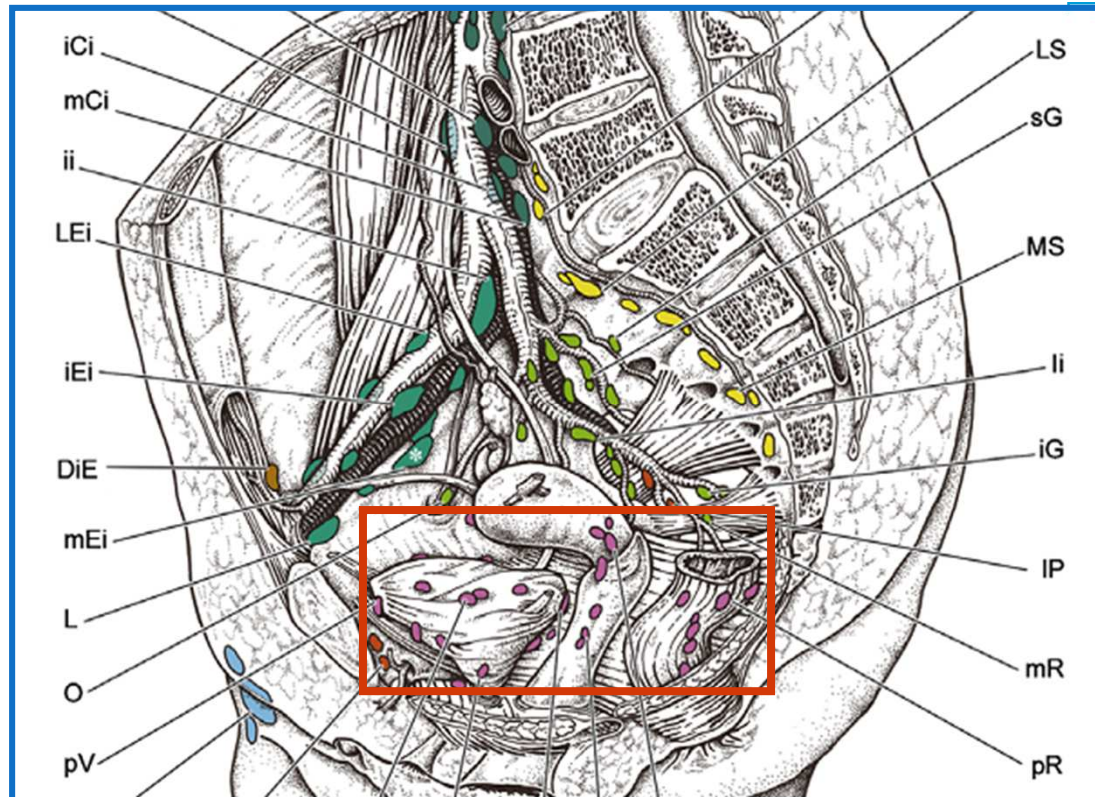
Pelvic Lymph Nodes

Anatomical description

- ❑ **Pelvic lymph nodes :**
- ❑ **Parietal lymphatics**
 - ❑ Superficial parietal
 - ❑ Deep parietal
- ❑ **Visceral lymphatics**
 - ❑ First located close to the viscera,
 - ❑ Then around the vascular pedicles of each organ
 - ❑ And then finally along the large iliac vessels

Pelvic Lymph Nodes

Anatomical description



Visceral lymphatics

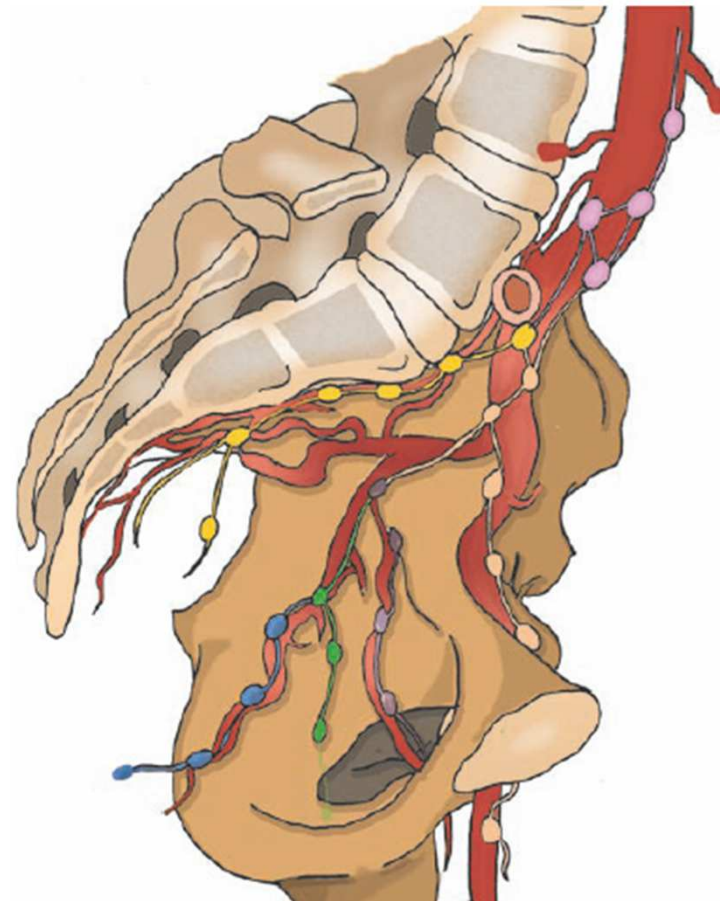
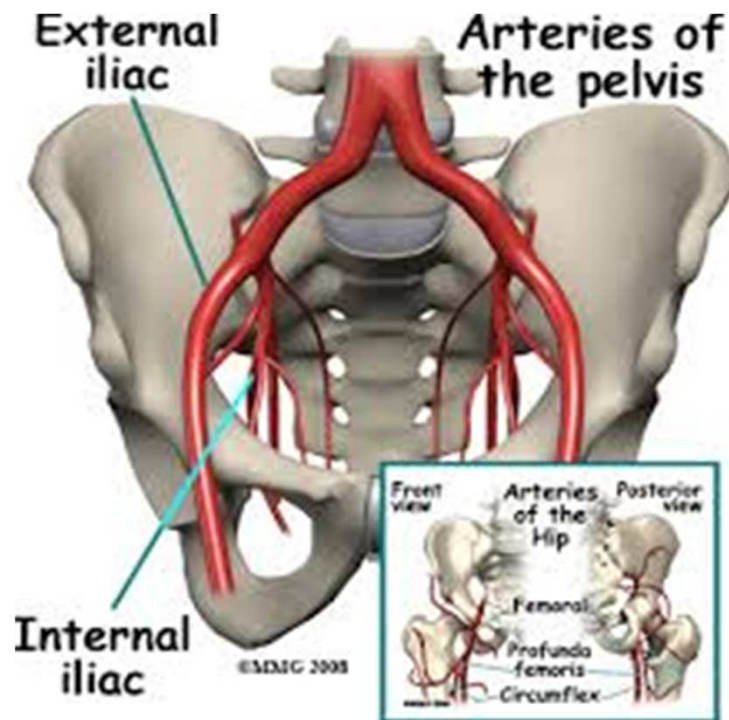
□ Juxtavisceral nodes

- Vesical nodes – pre, lateral, post & subvesical
- Paravaginal and parauterine nodes – lateral edge of vagina & cervix
- Pararectal nodes – right & left aspects of rectum

Pelvic Lymph Nodes

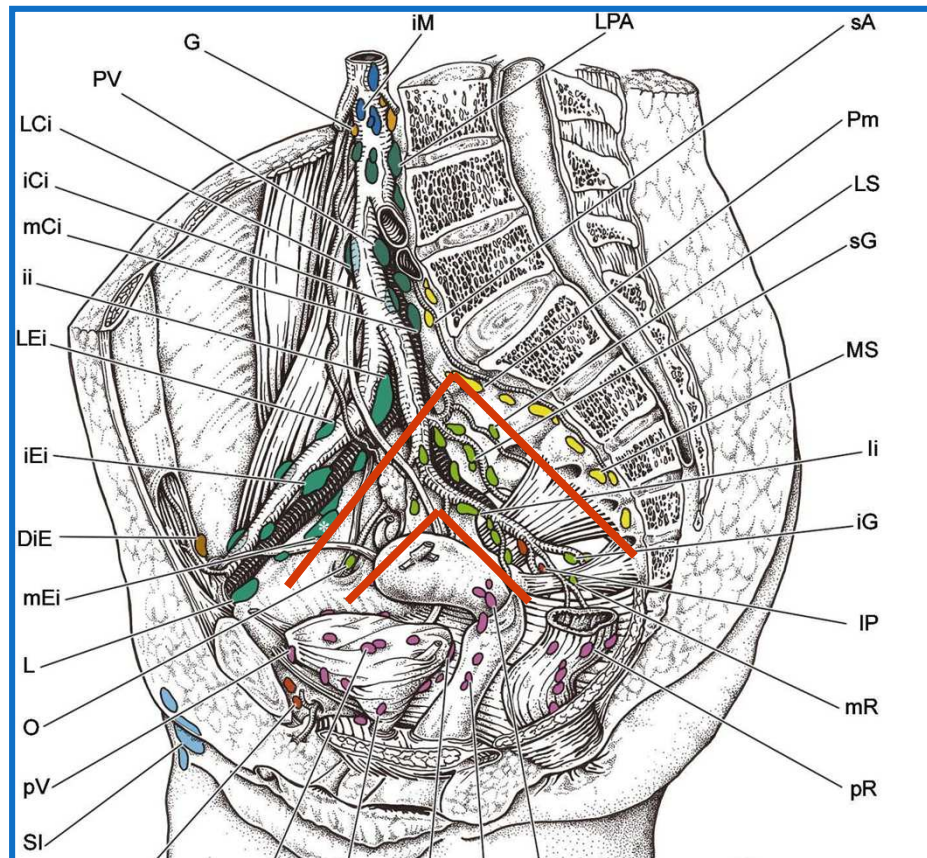
Anatomical description

- Along the large iliac vessels



Pelvic Lymph Nodes

Anatomical description



Internal iliac

(hypogastric nodes)

- Posterior part of prostate
- Body of the uterus
- Lat & lower part of urinary bladder
- Middle and lower vagina
- Membranous & prostatic segments of the urethra
- Middle part of rectum

Pelvic Lymph Nodes

Internal iliac

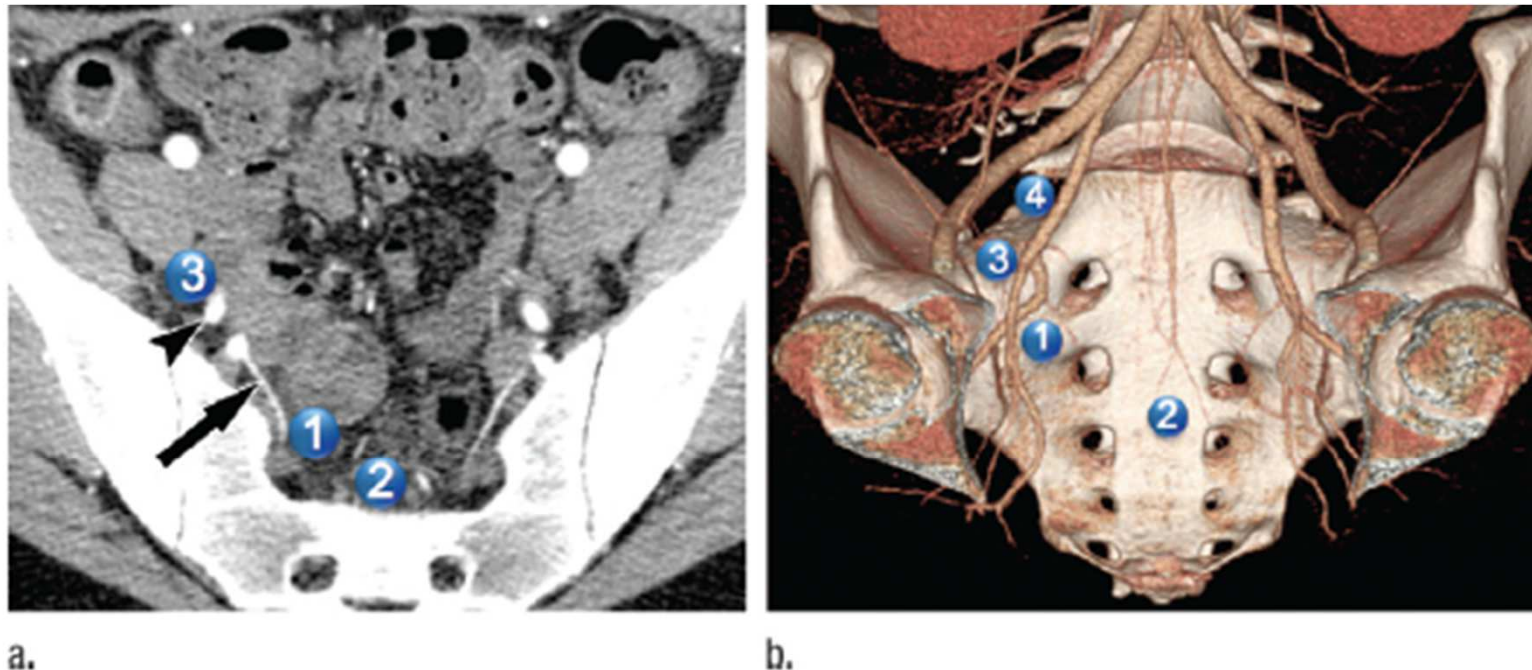
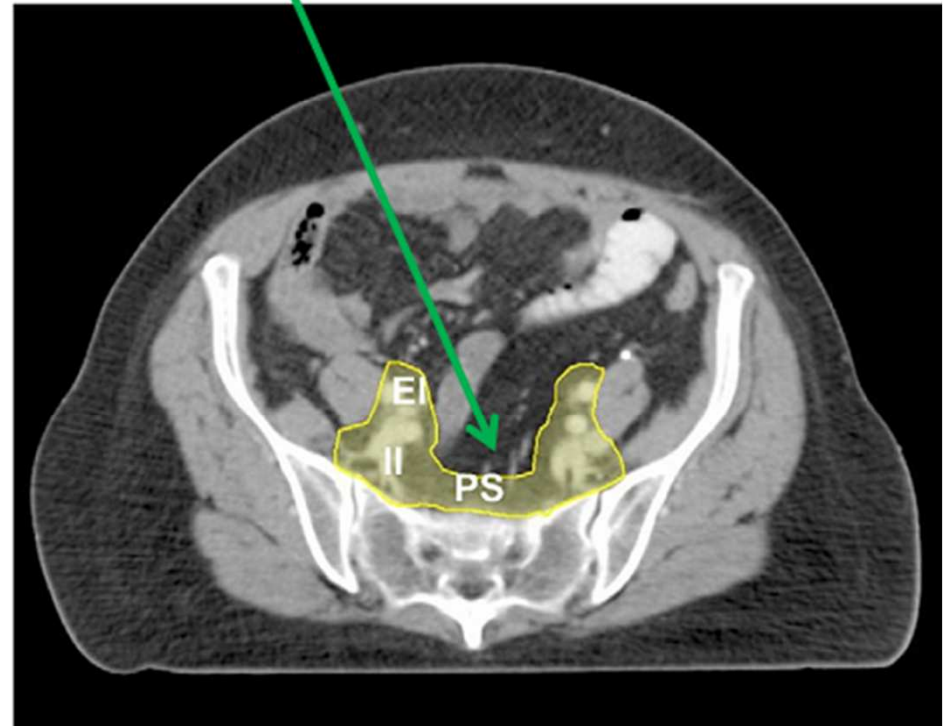
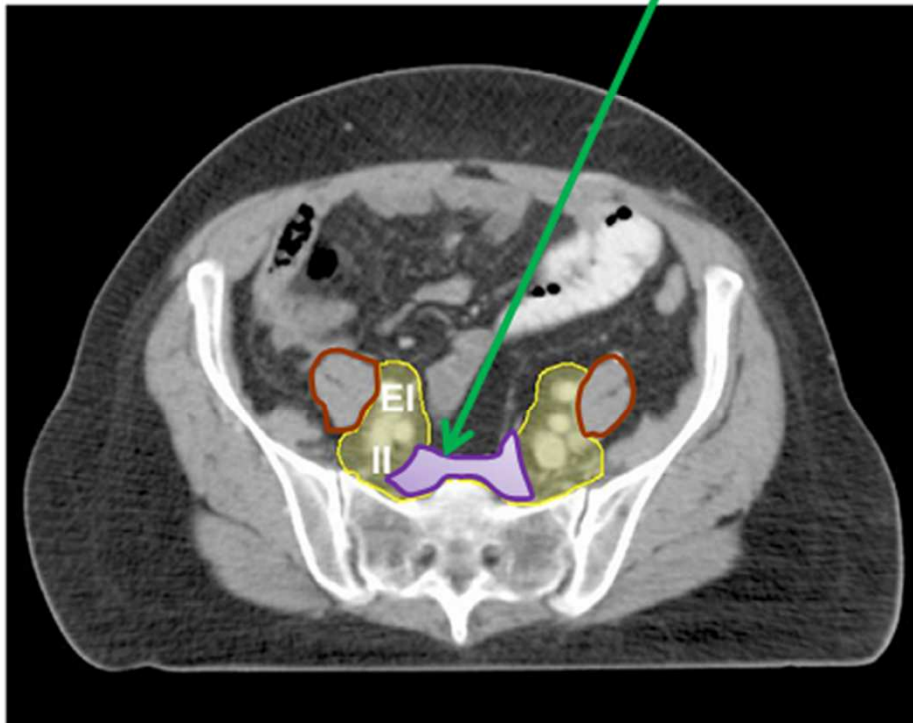


Figure 3: Internal iliac lymph nodes. **(a)** Axial contrast-enhanced CT image and **(b)** volume-rendered reformation of contrast-enhanced CT image show location of named subgroups of internal iliac lymph nodes: 1 = lateral sacral, which are adjacent to lateral sacral artery (arrow); 2 = presacral; 3 = anterior, which are anterior to anterior division of internal iliac artery (arrowhead); 4 = hypogastric.

Anatomical considerations

Pre sacral Lymph nodes



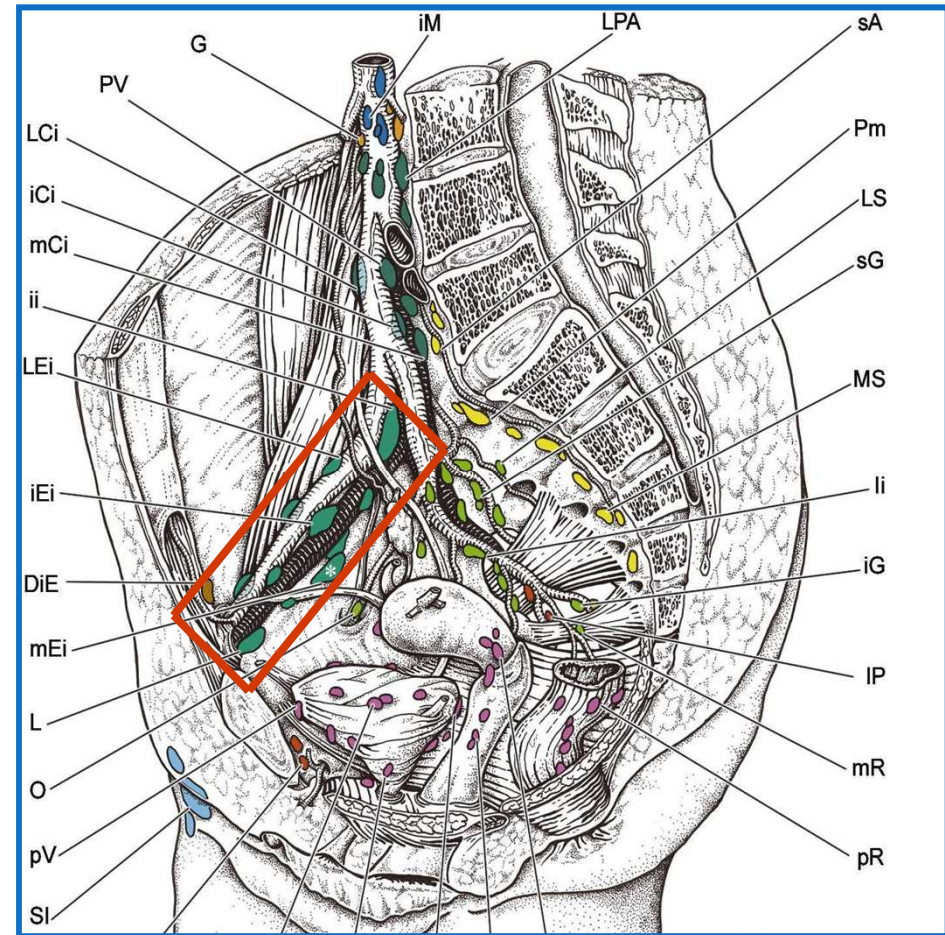
Pelvic Lymph Nodes

Anatomical description

□ External iliac

- Lower limb
- Lateral lobes of Prostate
- Cervix
- Upper part of vagina
- Fundus of urinary bladder

- Lateral external iliac
- Middle external iliac
- Medial external iliac



Pelvic Lymph Nodes

External iliac

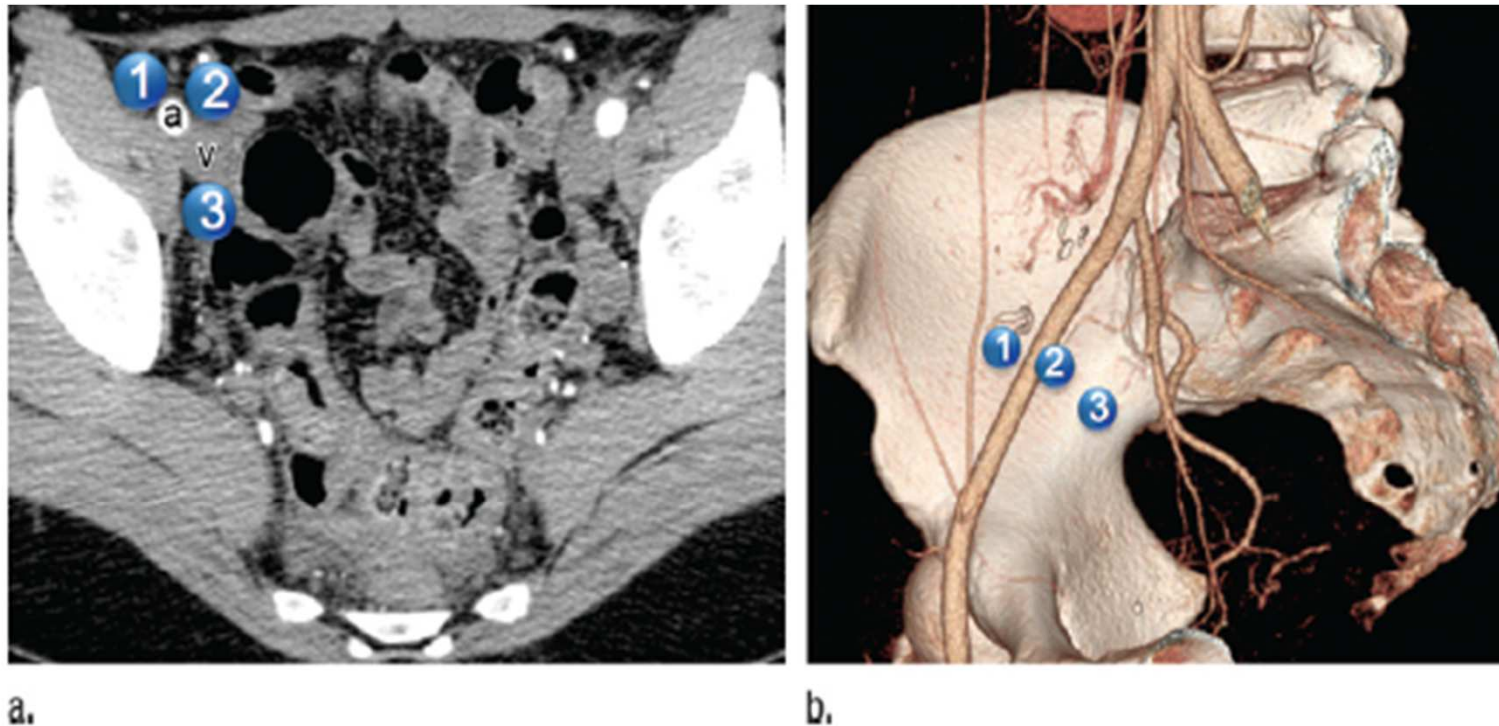
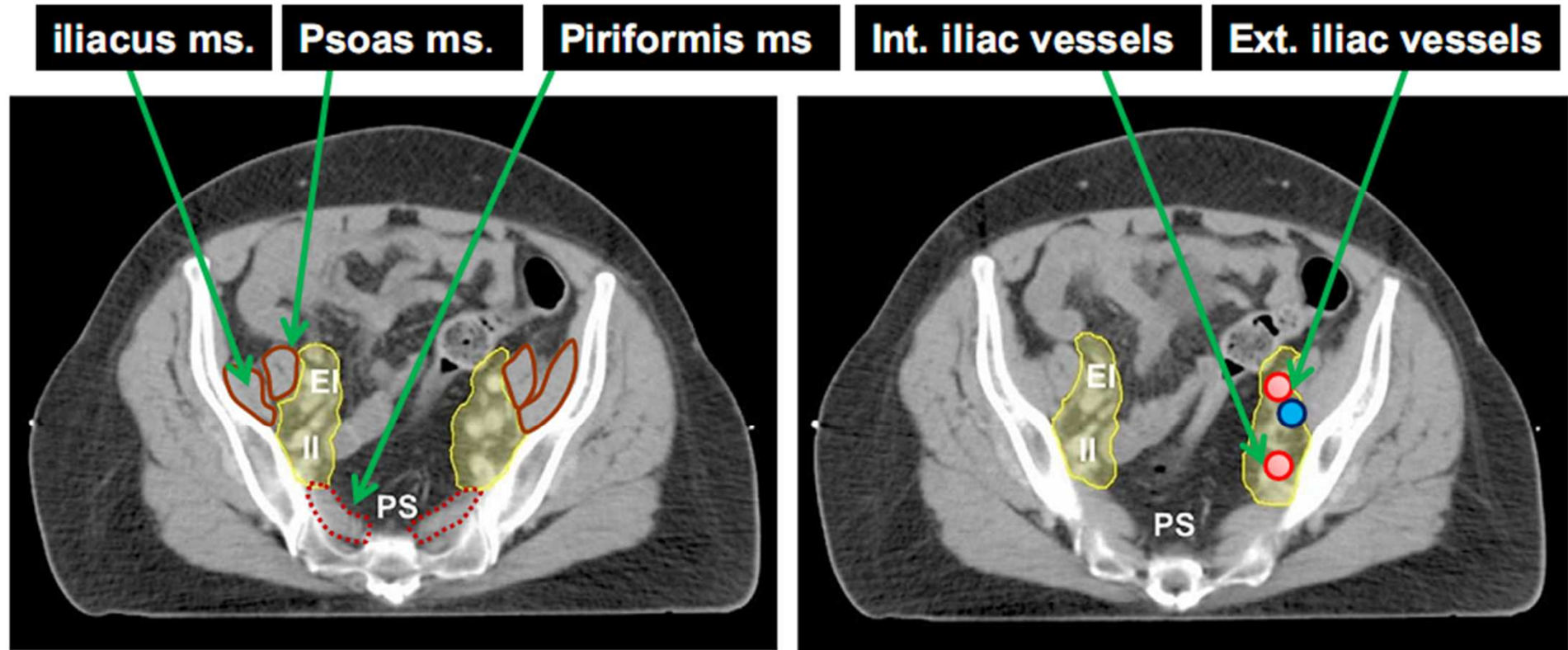


Figure 2: External iliac lymph nodes. (a) Axial contrast-enhanced CT image and (b) volume-rendered reformation of contrast-enhanced CT image show location of named subgroups of external iliac lymph nodes: 1 = lateral, 2 = middle, 3 = medial (including obturator). The relationship of these node locations to external iliac artery (a) and vein (v) can be seen.

Anatomical considerations



Pelvic Lymph Nodes

Anatomical description

□ Common iliac

□ Lateral common iliac

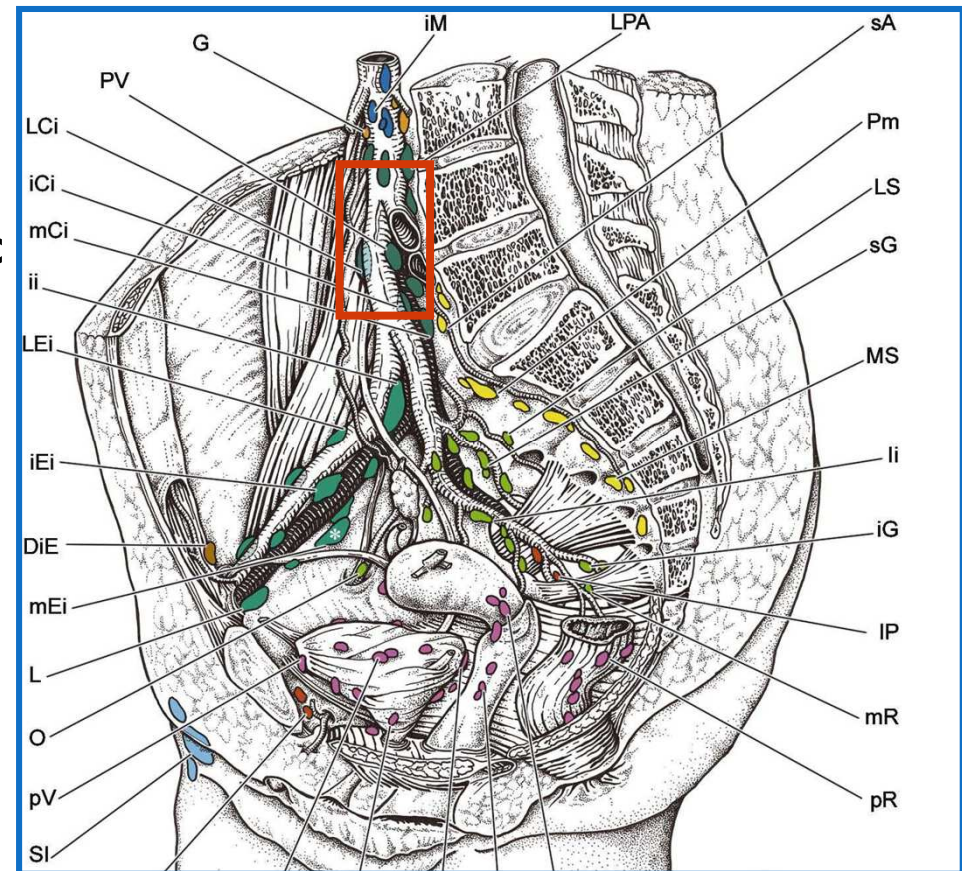
- Extension from external iliac

□ Middle common iliac

- Extension from internal iliac

□ Medial common iliac (subaortic)

- Cervix
- Bladder neck
- Posterior rectum



Pelvic Lymph Nodes

Common iliac

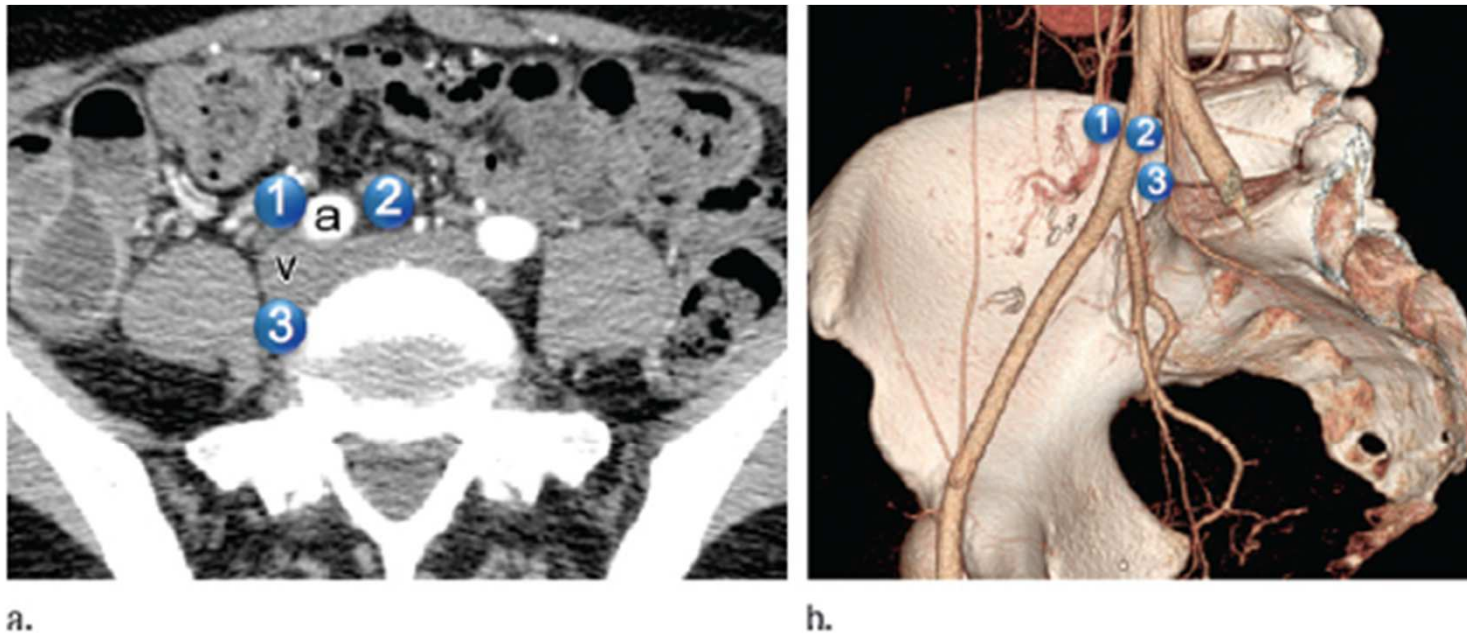
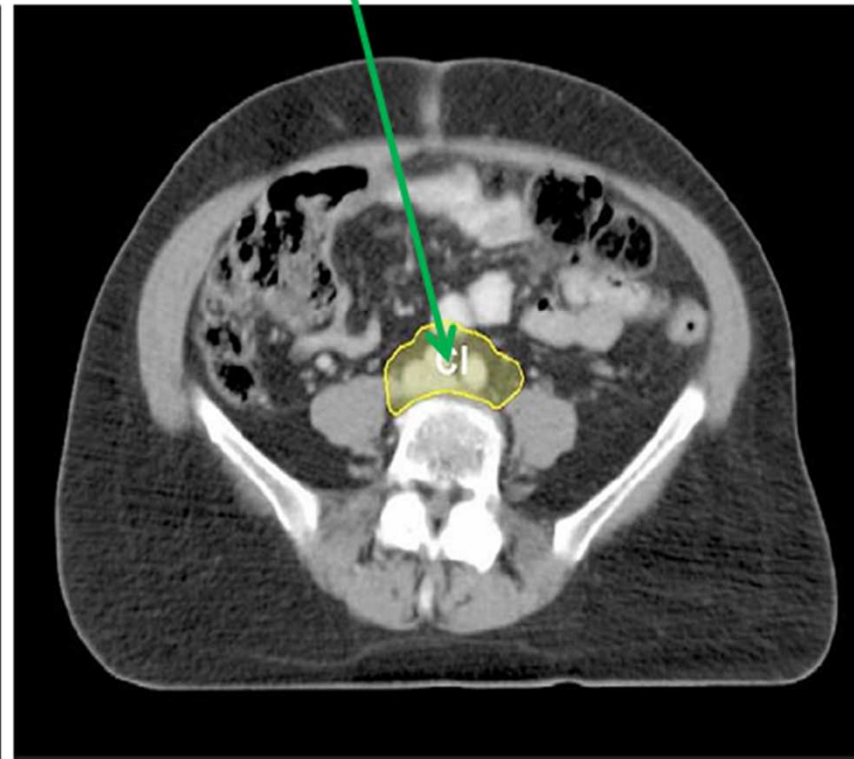
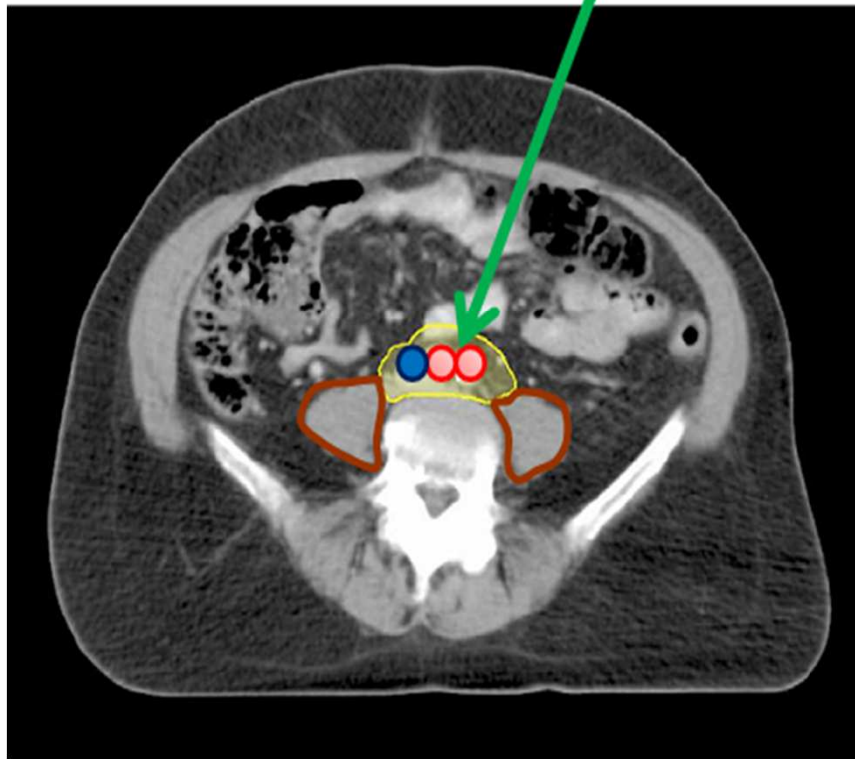


Figure 1: Common iliac lymph nodes. (a) Axial contrast material-enhanced computed tomographic (CT) image and (b) volume-rendered reformation of contrast-enhanced CT image show locations of named subgroups of common iliac lymph nodes: 1 = lateral, 2 = medial, 3 = middle. The relationship of these node locations to common iliac artery (a) and vein (v) can be seen.

Anatomical considerations

Aortic Bifurcation = Common iliacs



Inguinal Lymph Nodes

- ❑ The inguinal ligament at the origin of inferior epigastric vessels and circumflex iliac vessels is used as a landmark for distinguishing the deep inguinal nodes from the medial chain of the external iliac
- ❑ **Superficial inguinal nodes**
 - External genitalia
 - Anus
 - Superficial perineum
- ❑ **Deep inguinal nodes**
 - Lymphatics from Sup inguinal lymph nodes
 - Glans & Clitoris
 - Some deep lymphatics of lower limb

Inguinal Lymph Nodes

- ❑ Inguinal Lymph Node involvement:

- ❑ Vulva
- ❑ Urethra
- ❑ Penis
- ❑ Distal Rectum
- ❑ Anal Canal
- ❑ Distal one-third of vagina

Inguinal Lymph Nodes

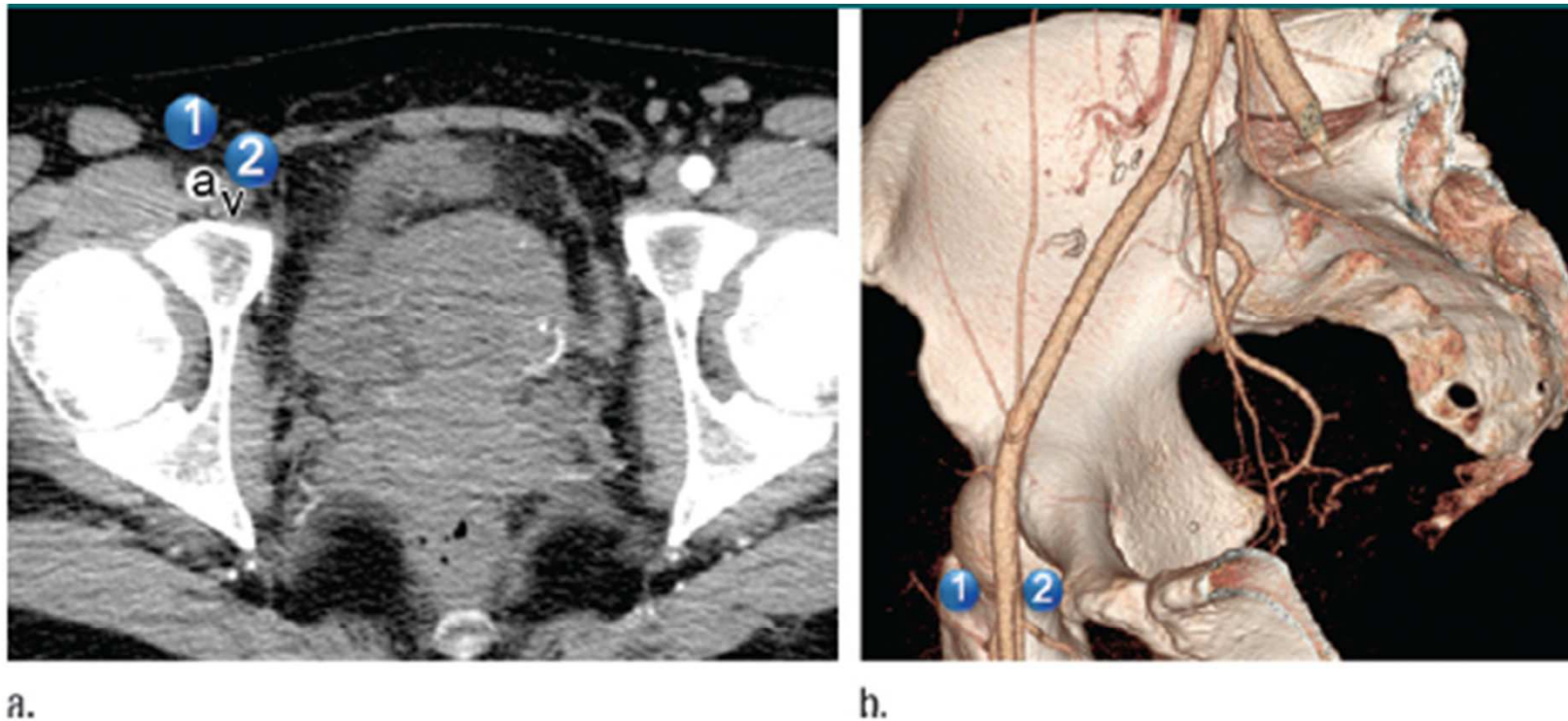


Figure 4: Inguinal lymph nodes. (a) Axial contrast-enhanced CT image and (b) volume-rendered reformation of contrast-enhanced CT image show location of named subgroups of inguinal lymph nodes: 1 = superficial, 2 = deep. The relationship of these node locations to common femoral artery (a) and vein (v) can be seen.

Regional Nodes of Pelvic Tumors

Regional Nodes of Pelvic Tumors

Nodes	Anus	Bladder	Cervix	Endometrium	Ovary	Penis	Prostate	Rectum	Testis	Vagina	Vulva
Perivisceral	Regional	Regional	Regional	Regional	Regional	Regional	Regional	Regional	Regional	Regional	Regional
Inguinal	Regional	Non	Non	Non	Non	Regional	Non	Non	Regional*	Regional	Regional
Internal iliac	Regional	Regional	Regional	Regional	Regional	Regional	Regional	Regional	Non	Regional	Non
External iliac	Non	Regional	Regional	Regional	Regional	Regional	Regional	Non	Regional*	Regional	Non
Common iliac	Non	Non	Regional	Regional	Regional	Non	Non	Non	Non	Non	Non
Paraortic	Non	Non	Non	Regional	Regional	Non	Non	Non	Regional	Non	Non

Source.—Reference 24.

Note.—Non = nonregional.

* Regional only in setting of previous scrotal or inguinal surgery.

Gynaecological Cancers

- ❑ The nodal CTV for cervix would typically include :
 - ❑ **External iliac** nodes
 - ❑ **Internal iliac** nodes
 - ❑ **Obturator** nodes
 - ❑ **Common iliac** nodes for tumours involving the cervix
 - ❑ **Distal lateral external iliac** nodes, if other external iliac nodes are involved, or if the target volume also includes the inguinal regions.
 - ❑ **Lower pre-sacral** nodes, if there is tumour extension along the uterosacral ligaments or if there is rectal involvement

Lymph node group & recommended margins:

- ❑ **Common iliac** - 7 mm margin around vessels. Extend posterior and lateral borders to psoas and vertebral body
- ❑ **External iliac** - 7 mm margin around vessels. (Extend anterior border by a further 10 mm anterolaterally along the iliopsoas muscle to include the lateral external iliac nodes)
- ❑ **Internal iliac** - 7 mm margin around vessels. Extend lateral borders to pelvic side wall
- ❑ **Obturator**- Join external and internal iliac regions with a 17 mm wide strip along the pelvic side wall
- ❑ **Pre-sacral Subaortic** -10 mm strip over anterior sacrum
- ❑ **Mesorectal**- cover entire mesorectal space

Margins around vessels

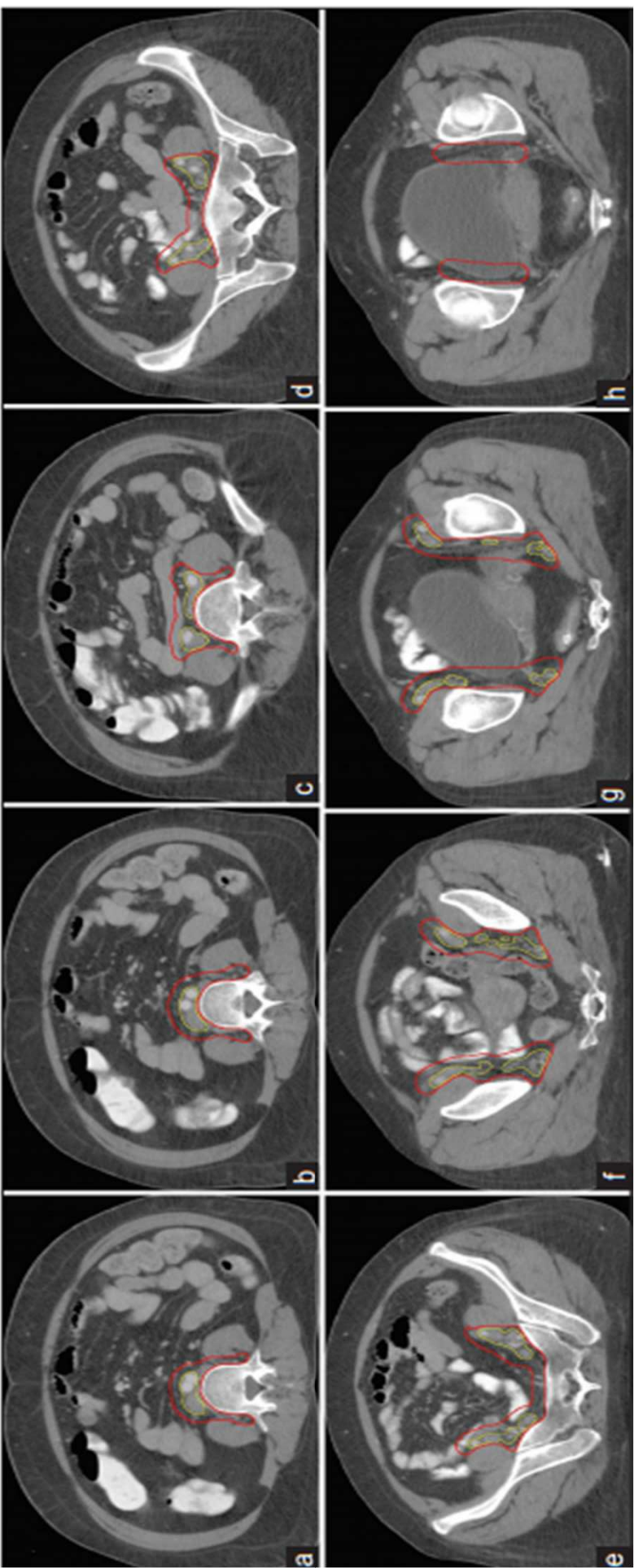
Lymph node contours covered by margin around blood vessels

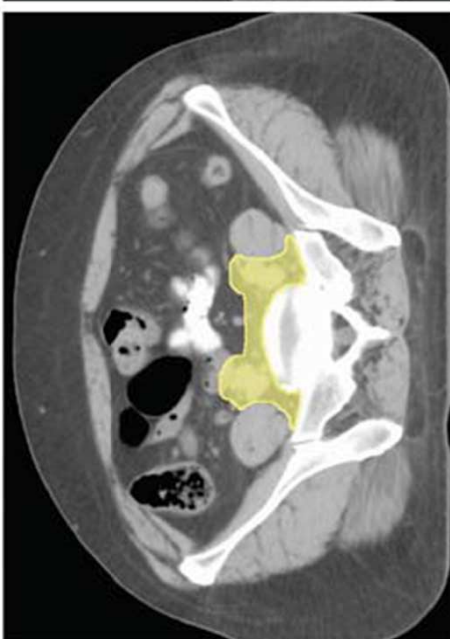
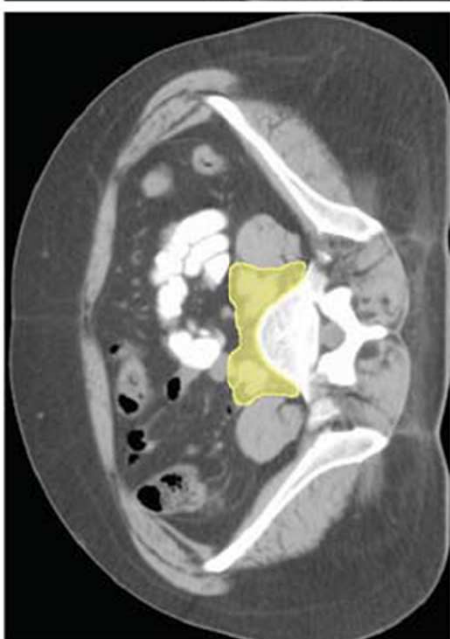
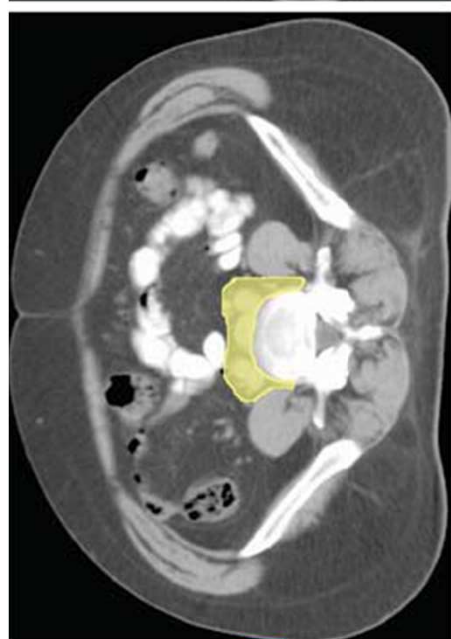
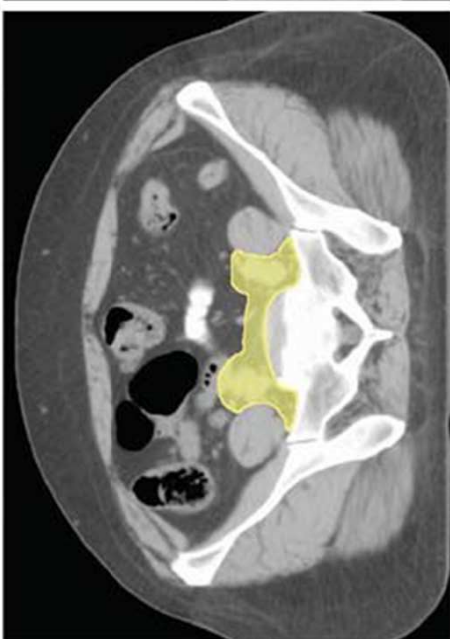
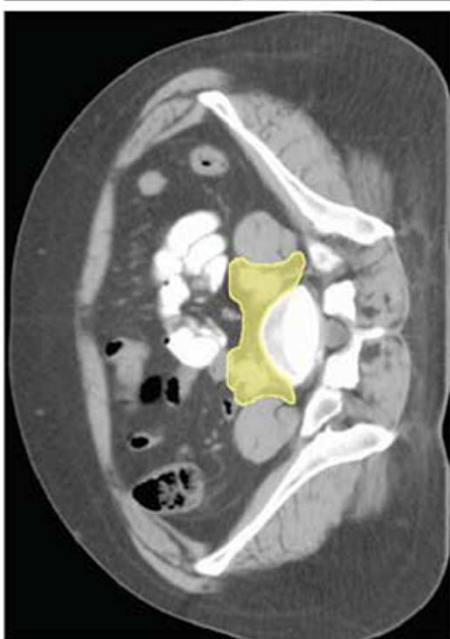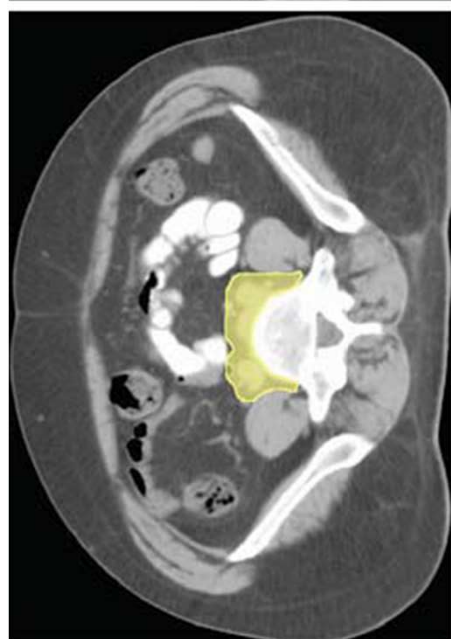
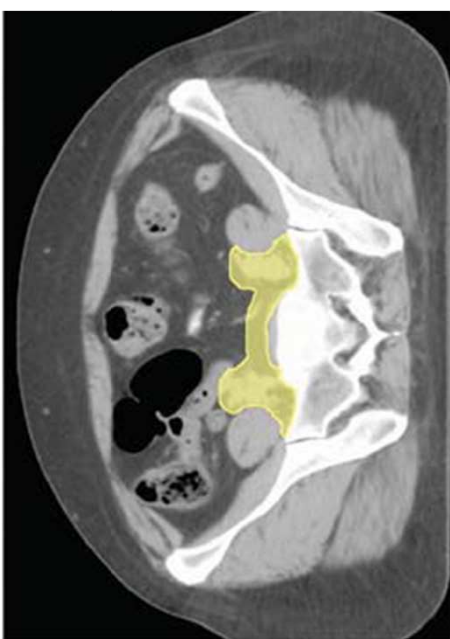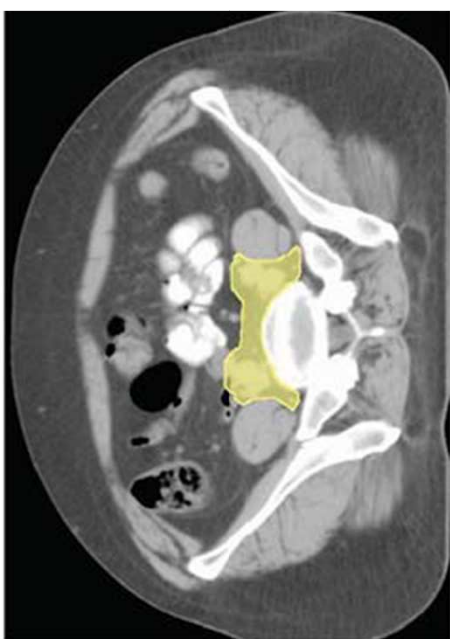
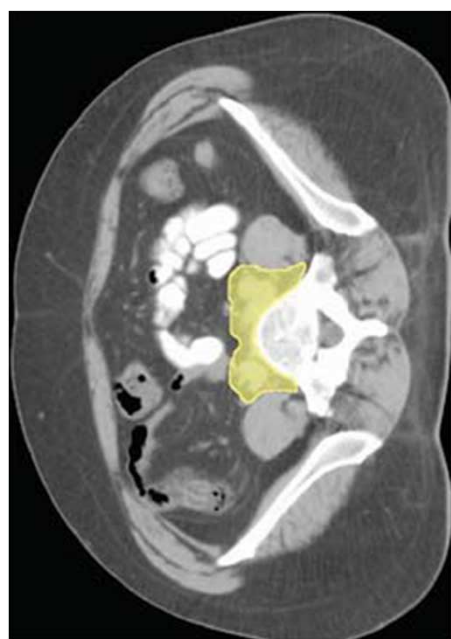
Lymph node group	3 mm (%)	5 mm (%)	7 mm (%)	10 mm (%)	15 mm (%)
Common iliac (<i>n</i> = 135)	41 (30.3)	90 (66.7)	123 (91.1)	135 (100)	135 (100)
Medial external iliac (<i>n</i> = 196)	122 (62.2)	167 (85.2)	193 (98.4)	196 (100)	196 (100)
Anterior external iliac (<i>n</i> = 241)	124 (51.4)	190 (78.8)	227 (94.2)	241 (100)	241 (100)
Lateral external iliac (<i>n</i> = 190)	16 (8.4)	41 (21.6)	<u>76 (40)</u>	<u>123 (64.7)</u>	178 (93.7)
Obturator (<i>n</i> = 303)	275 (90.1)	295 (97.3)	302 (99.7)	303 (100)	303 (100)
Internal iliac (<i>n</i> = 144)	105 (72.9)	135 (93.8)	142 (98.6)	144 (100)	144 (100)
Presacral (<i>n</i> = 7)	0 (0)	0 (0)	<u>3 (42.9)</u>	<u>3 (42.9)</u>	3 (42.9)
Total (<i>n</i> = 1216)	683 (56.2)	918 (75.7)	1066 (87.7)	1145 (94.2)	1200 (98.7)

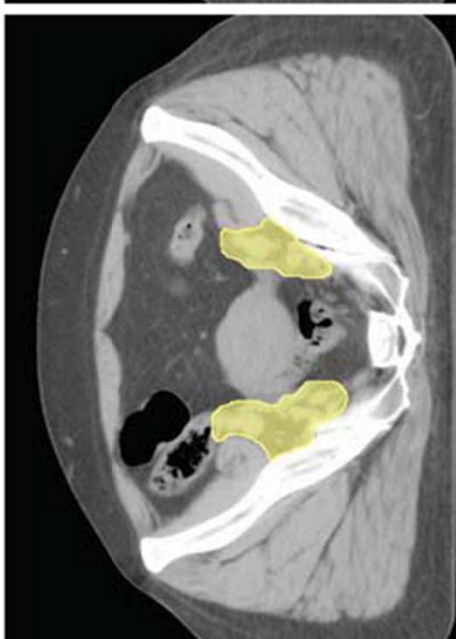
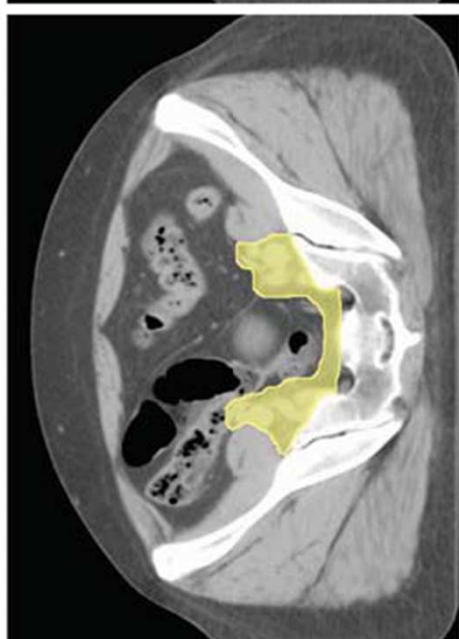
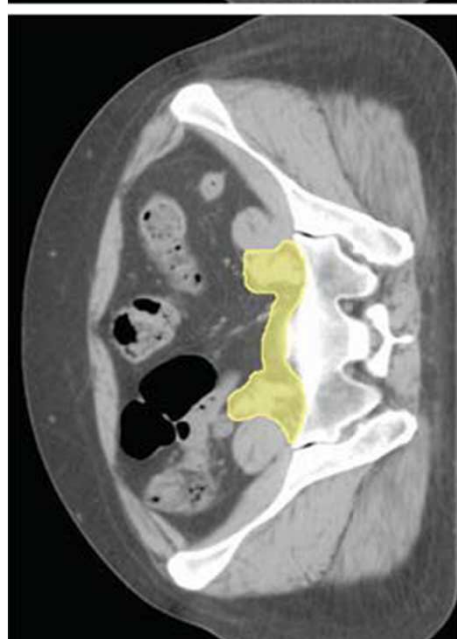
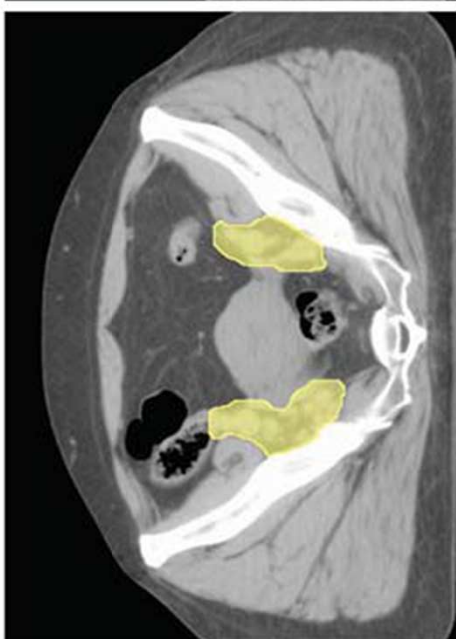
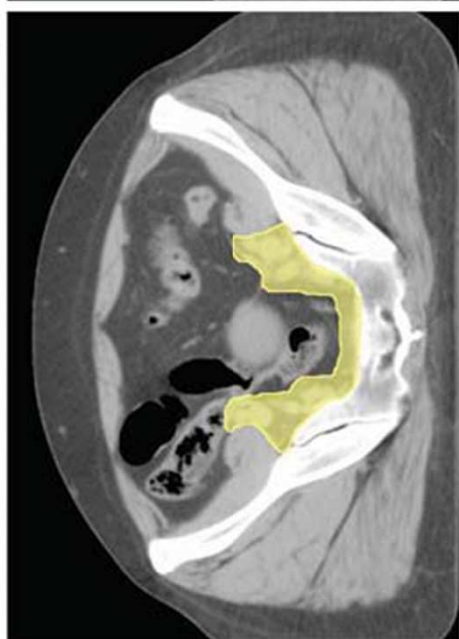
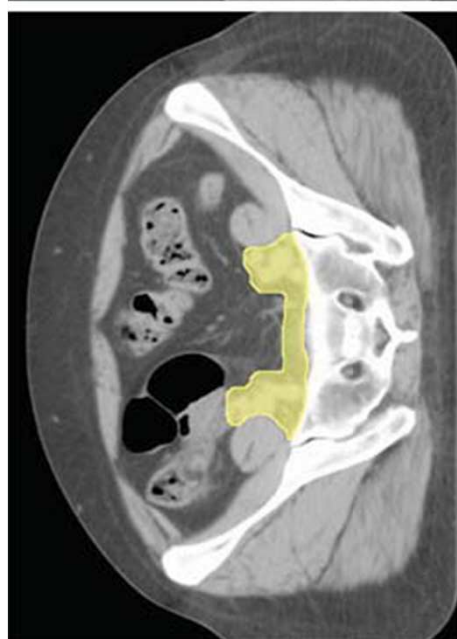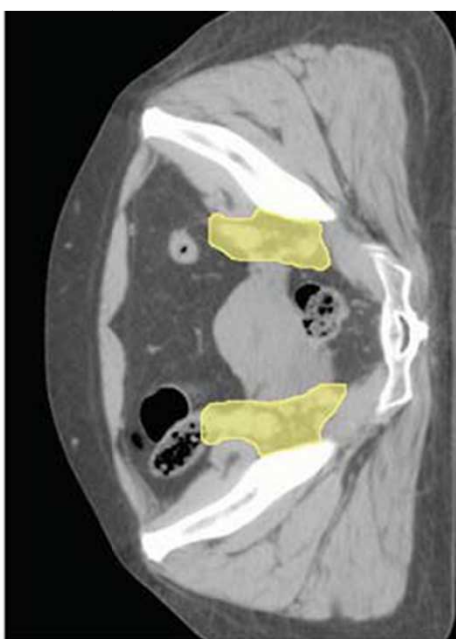
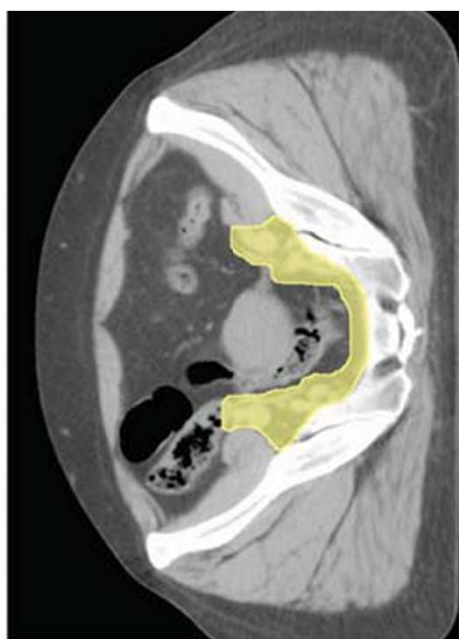
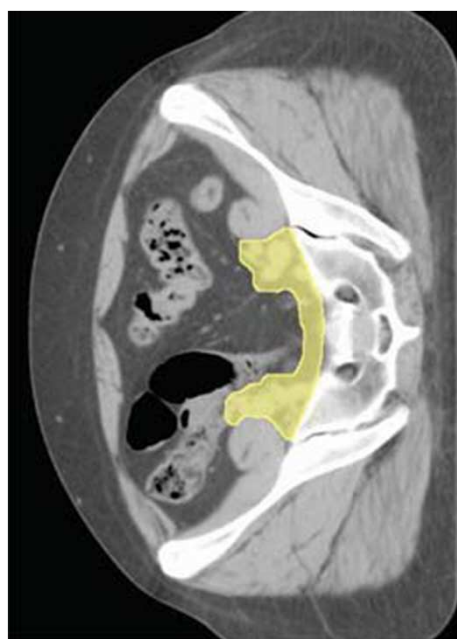Margins around vessels

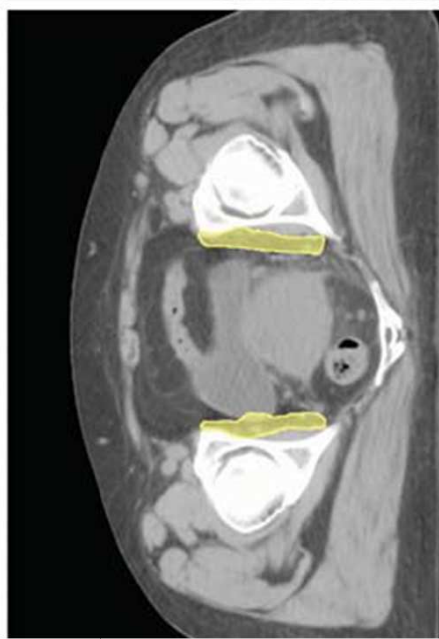
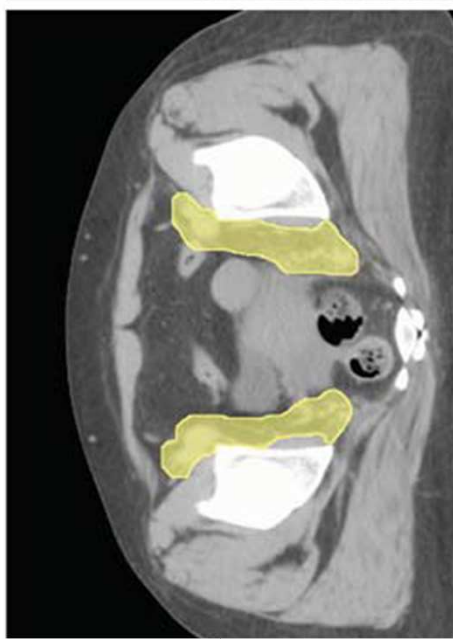
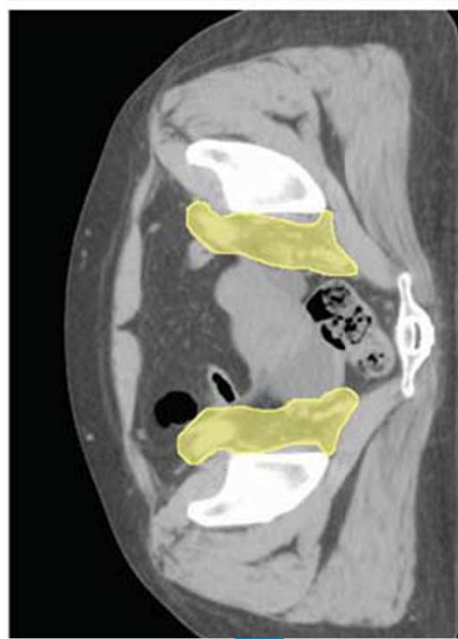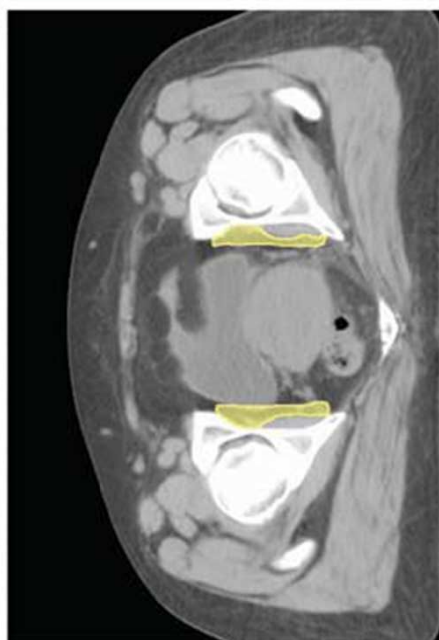
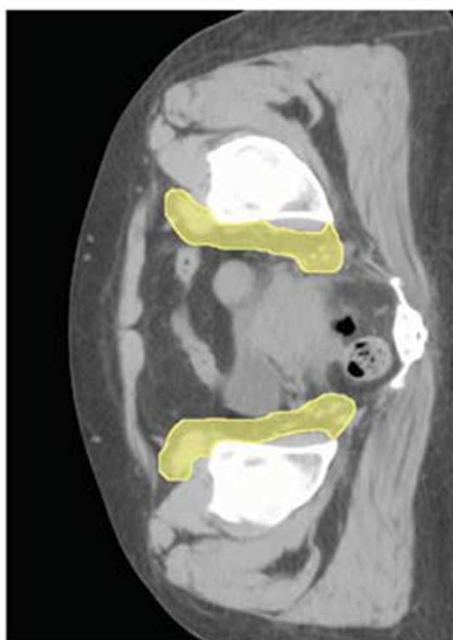
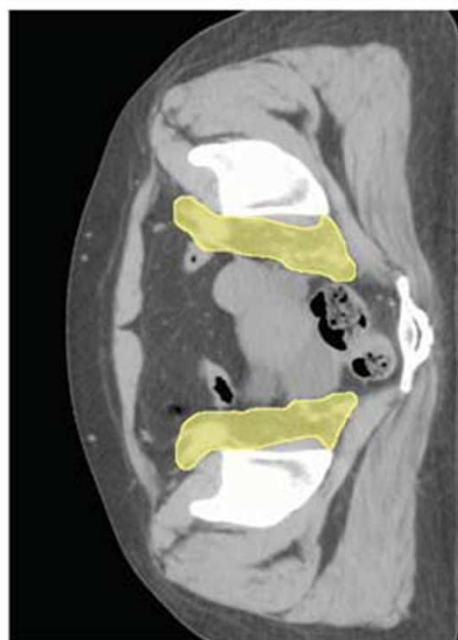
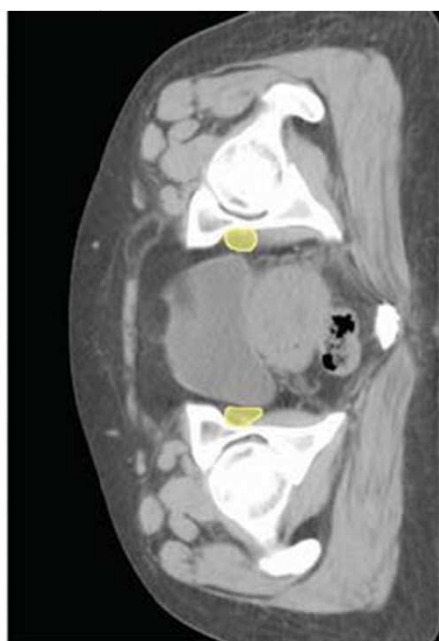
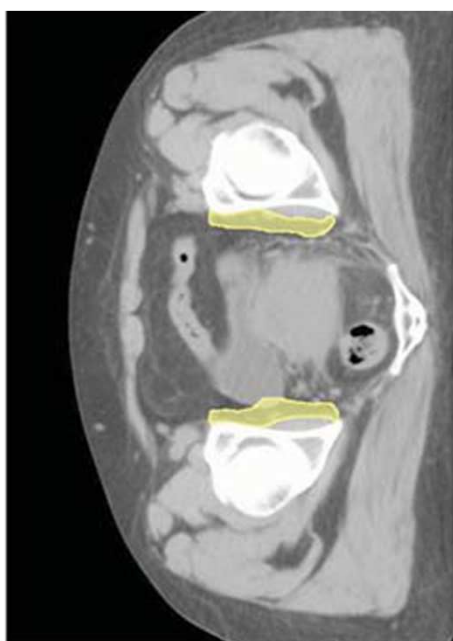
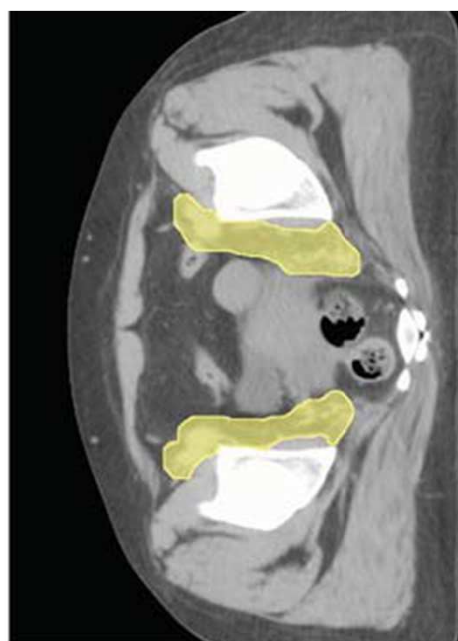
Volume of normal structures within clinical target volumes (CTV) and planning target volumes (PTV)

A. Mean volume of normal structure within CTV (cm ³)											
	Total volume	3 mm	(%)	5 mm	(%)	7 mm	(%)	10 mm	(%)	15 mm	(%)
Bowel	643.7	5.9	(0.9)	16.8	(2.6)	32.4	(5.1)	63.2	(10.2)	123.3	(19.9)
Bladder	131.0	0.7	(0.3)	2.1	(1.0)	3.9	(1.9)	7.4	(3.8)	14.3	(7.7)
Rectum	44.4	0.2	(0.2)	0.5	(0.7)	0.9	(1.4)	2.2	(3.6)	5.4	(9.7)
B. Mean volume of normal structure within PTV (cm ³)											
	Total volume	3 mm	(%)	5 mm	(%)	7 mm	(%)	10 mm	(%)	15 mm	(%)
Bowel	643.7	95.6	(15.4)	120.7	(19.4)	146.9	(23.7)	190.3	(30.8)	265.9	(42.9)
Bladder	131.0	13.1	(7.5)	16.7	(9.8)	21.2	(12.8)	28	(17.5)	40.6	(26.5)
Rectum	44.4	3.9	(6.8)	5.5	(19.9)	7.2	(13.3)	10.4	(19.9)	17.1	(34.1)



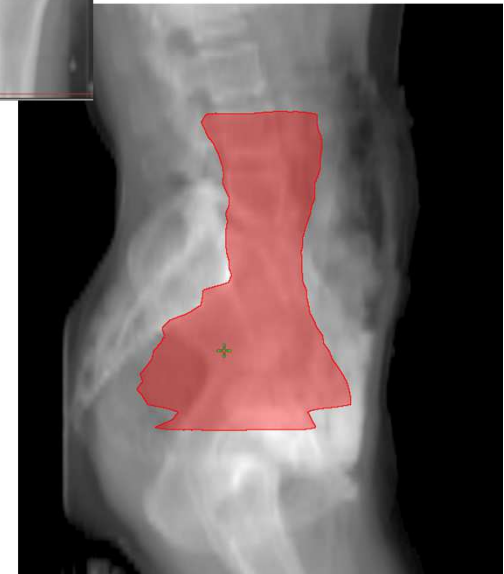
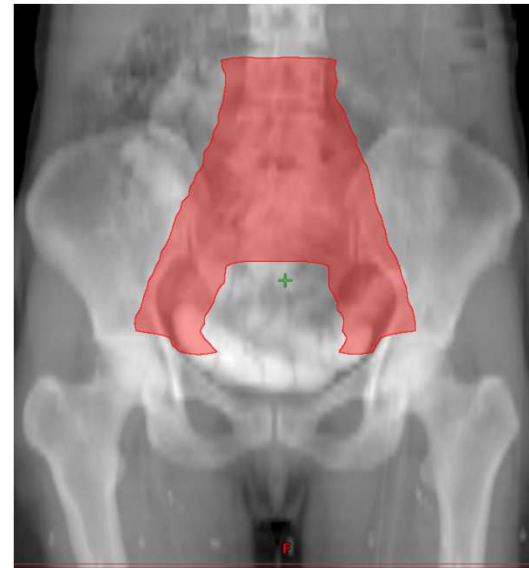




Gynaecological Cancers

- ❑ **The nodal CTV**
 - ❑ **External iliac** nodes
 - ❑ **Internal iliac** nodes
 - ❑ **Obturator** nodes
 - ❑ **Common iliac** nodes
 - ❑ **Distal lateral external iliac** nodes
 - ❑ **Lower pre-sacral** nodes,



Inguinal Lymph Nodes

For inguinal lymph nodes:

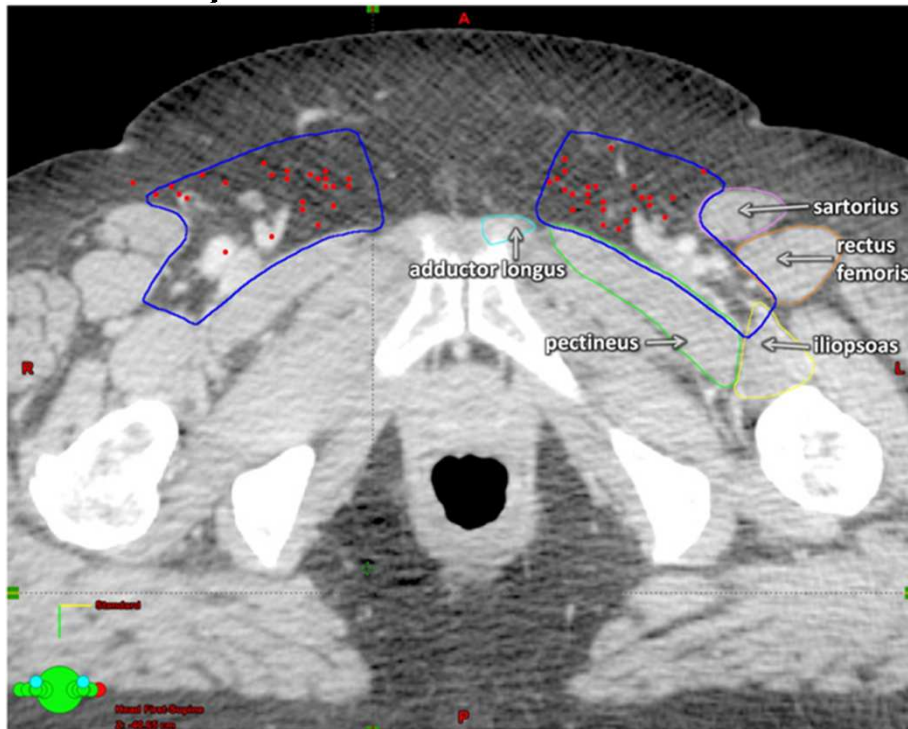
- ❑ The femoral vessels provide the most appropriate structure around which the nodal group is located.
- ❑ The depth of the femoral arteries and/or groin nodes can be determined by computed tomography (CT) or magnetic resonance imaging and depends on the patient's body habitus and size.
- ❑ The mean femoral vessel depth was 6.1 cm, with a range of 2.0-18.5 cm

Inguinal Lymph Nodes

- ❑ Location of the nodes
- ❑ Relative to the femoral vessels: Margins required
 - ❑ 51.9% - Anteromedial - $\geq 35\text{mm}$
 - ❑ 21.2% - Anterior - $\geq 23\text{mm}$
 - ❑ 11.5% - Anterolateral - $\geq 25\text{mm}$
 - ❑ 9.6% - Medial - $\geq 22\text{mm}$
 - ❑ 3.9% - Lateral - ≥ 32
 - ❑ 1.9% - Posterior - $\geq 9\text{mm}$
- ❑ Hence margin required is **$> 2\text{cm}$** & is much more than **7-10mm** recommended for pelvic nodes

Inguinal Lymph Nodes

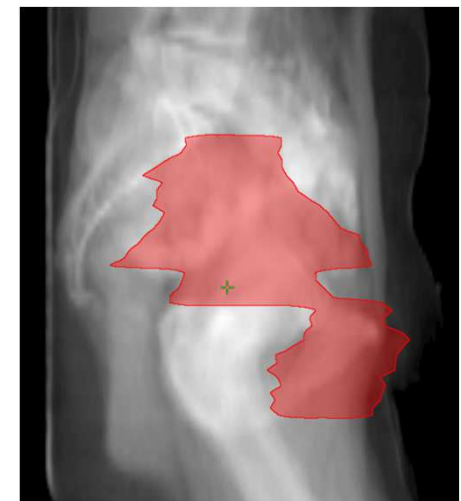
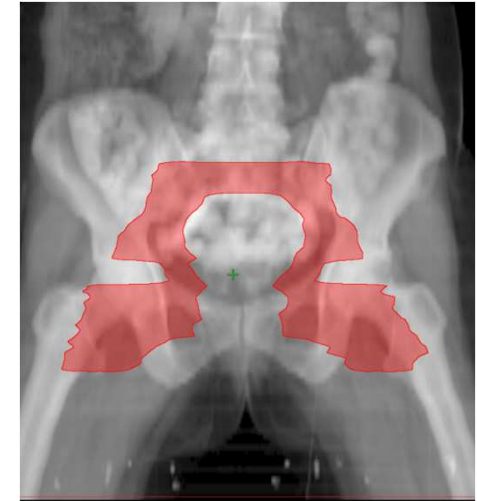
- Contouring as a compartment may be more reproducible



- Anatomic boundaries
 - Laterally, medial border of the iliopsoas;
 - Medially, lateral border of adductor longus or medial end of pectineus;
 - Posteriorly, iliopsoas muscle laterally and anterior aspect of the pectineus muscle;
 - Medially and anteriorly, the anterior edge of the sartorius muscle

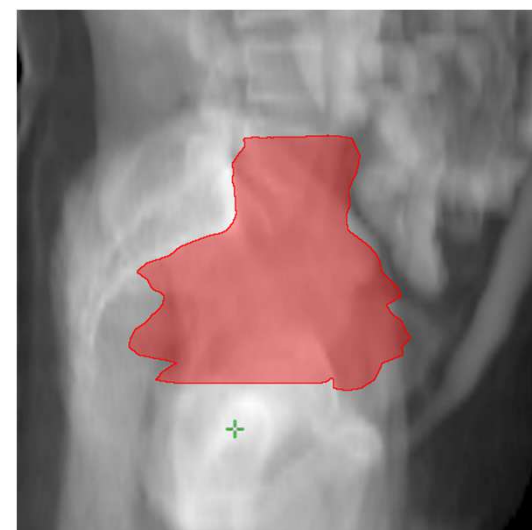
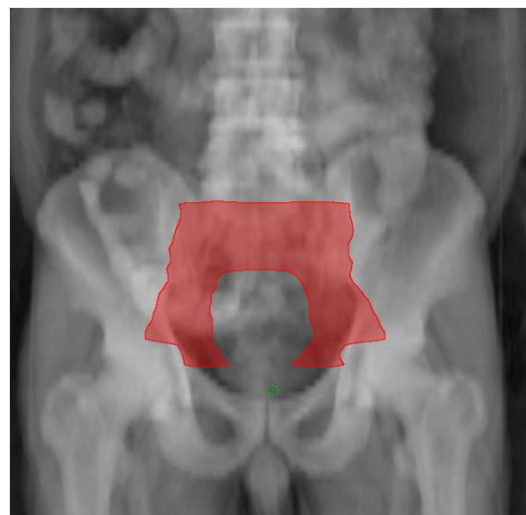Inguinal Lymph Nodes

- ❑ Caudal extent of the inguinal region should be 2 cm caudad to the saphenous-femoral junction.
- ❑ The transition between inguinal and external iliac regions is recommended to be at the level of the caudad extent of the internal obturator vessels, approximately at the level of the upper edge of the superior pubic rami.



Prostate Cancer

- ❑ Three main drainage patterns for the prostate.
 - ❑ Cranially to the internal iliac lymph nodes.
 - ❑ Laterally to the external iliac lymph nodes.
 - ❑ Posterior to the subaortic aspect of the presacral lymph nodes S1-S3
- ❑ With the **main drainage to the internal iliac & presacral nodes**



Prostate Cancer

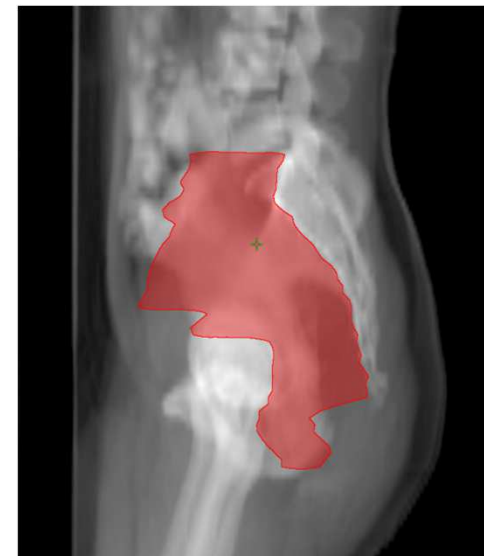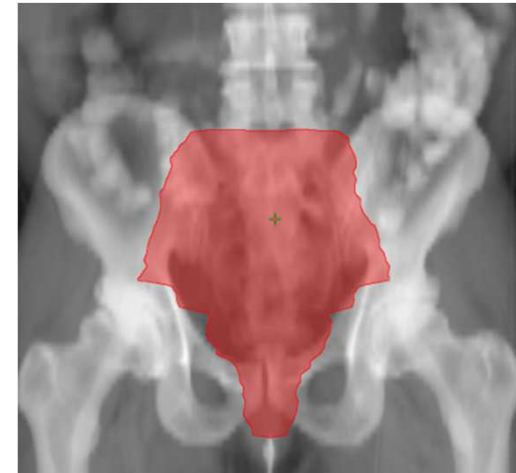
- ❑ Commence contouring at distal common iliac vessels at L5/S1 interspace
- ❑ Contour presacral LNs (subaortic only S1-3) posterior border being the anterior sacrum and anterior border approximately 10 mm anterior to the anterior sacral bone
- ❑ Place a 7mm margin around iliac vessels, carving out bowel, bladder and bone
- ❑ Stop external iliac contours at top of femoral heads (bony landmark for inguinal ligament)
- ❑ Stop contours of obturator LNs at top of symphysis pubis

Anorectal Cancer

- ❑ Target volumes for anal and rectal cancer differ substantially from those appropriate for gynecologic or genitourinary cancer.
- ❑ The most striking differences arise from the need for proper coverage of the **peri-rectal** and **pre-sacral** regions.
- ❑ The rectum and its associated mesentery are **avoidance** structures for GYN or GU malignancy, but represent **first echelon** drainage for both the anus and rectum.
- ❑ Therefore it is NOT sufficient to generate target volumes by a simple expansion about vessels and the rectum

Anorectal Cancer

- ❑ **CTVA:** internal iliac, pre-sacral, peri-rectal.
- ❑ **CTVB:** external iliac nodal region
- ❑ **CTVC:** inguinal nodal region
- ❑ **For rectal cancer**, in most cases, **CTVA** would be the only volume to receive elective radiation.
- ❑ **For anal cancers**, the elective regional target volume would include **all three**.



Anorectal Cancer

- ❑ **CTVA (perirectal, presacral, internal iliac regions)**
- ❑ *Lower pelvis.* The caudad extent of this elective clinical target volume should be a minimum of 2 cm caudad to gross disease. In addition there should be coverage of the entire mesorectum to the pelvic floor
- ❑ Unless there is radiographic evidence of extension into the ischiorectal fossa, extension of CTVA does not need to go more than a few millimeters beyond the levator muscles.

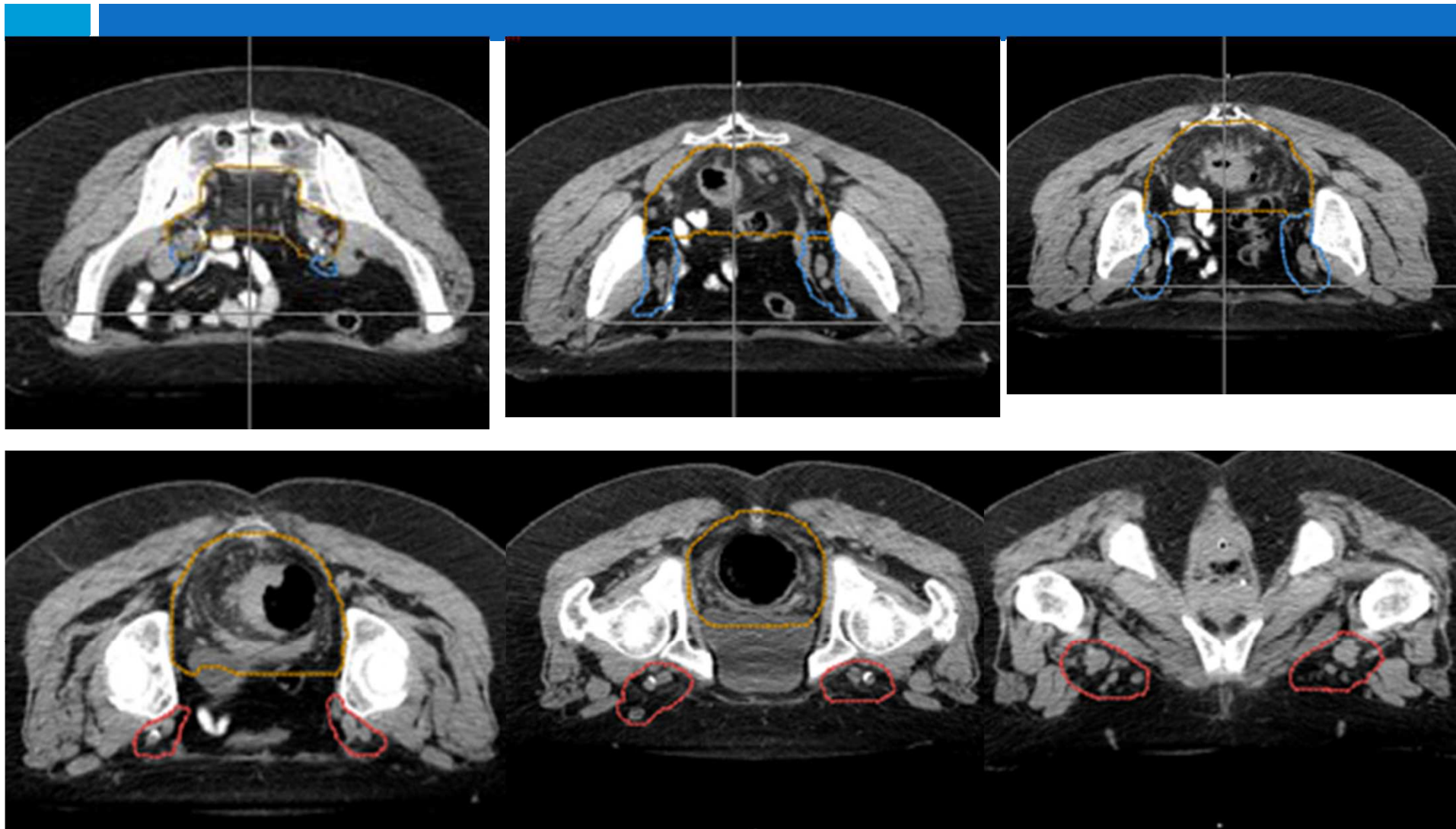
Anorectal Cancer

- ❑ *Mid-pelvis CTVA* includes the rectum and its mesentery, the internal iliac region, and a margin for bladder variability. The posterior and lateral margins should extend to pelvic sidewall musculature or, where absent, bone.
- ❑ *Upper pelvis* the rectosigmoid junction or at least 2 cm proximal to the superior extent of macroscopic disease whichever is more cephalad

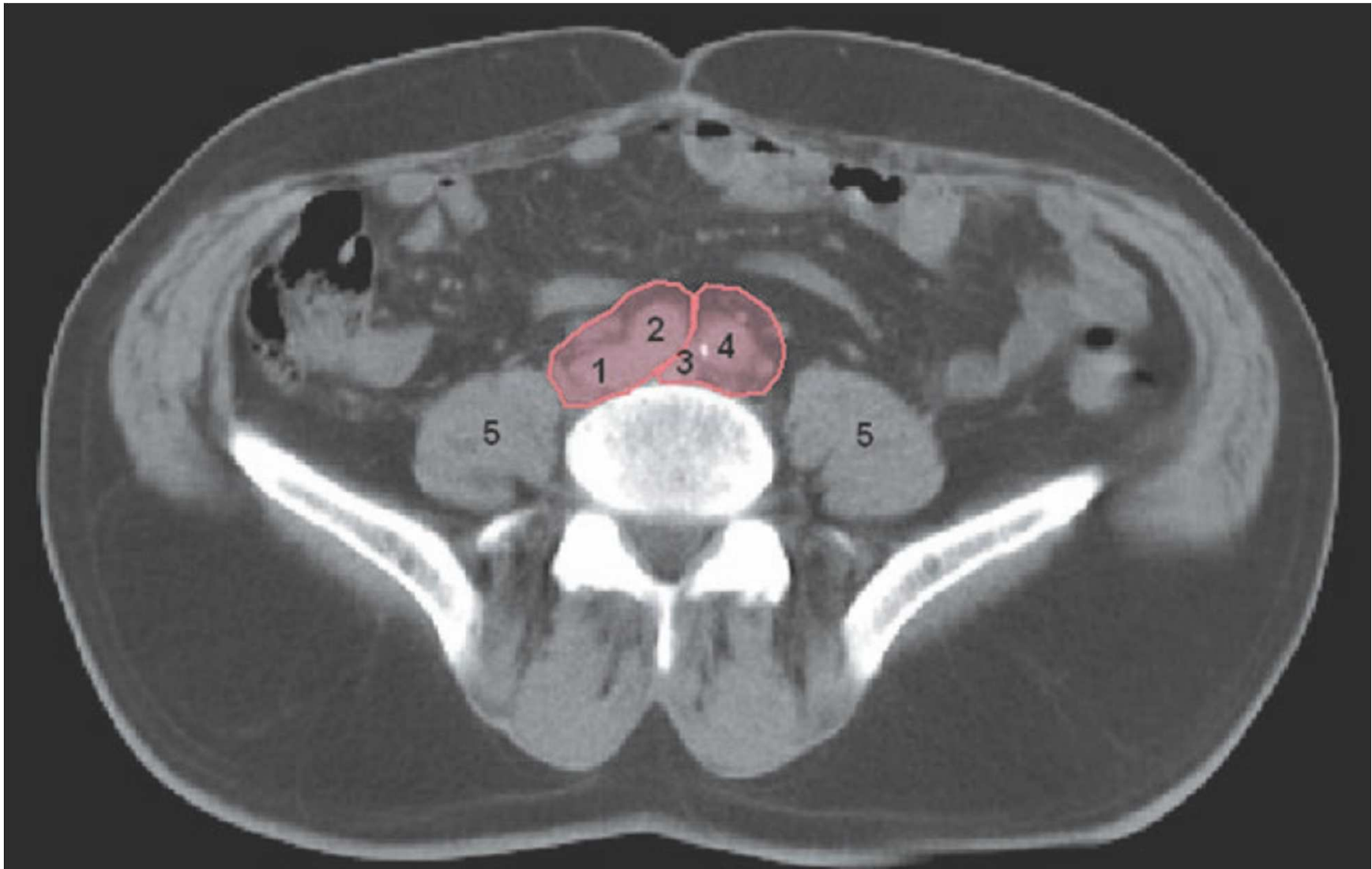
Anorectal Cancer

- ❑ The most cephalad aspect of CTV_A should be where the common iliac vessels bifurcate into external/internal iliacs (approximate bony landmark: sacral promontory).
- ❑ At midline, CTV_A should extend at least 1 cm anterior to the sacrum, to provide proper coverage of the presacral region.
- ❑ The most cephalad extent of CTV_A will be higher than the rectum, to properly cover the internal iliac and presacral regions.

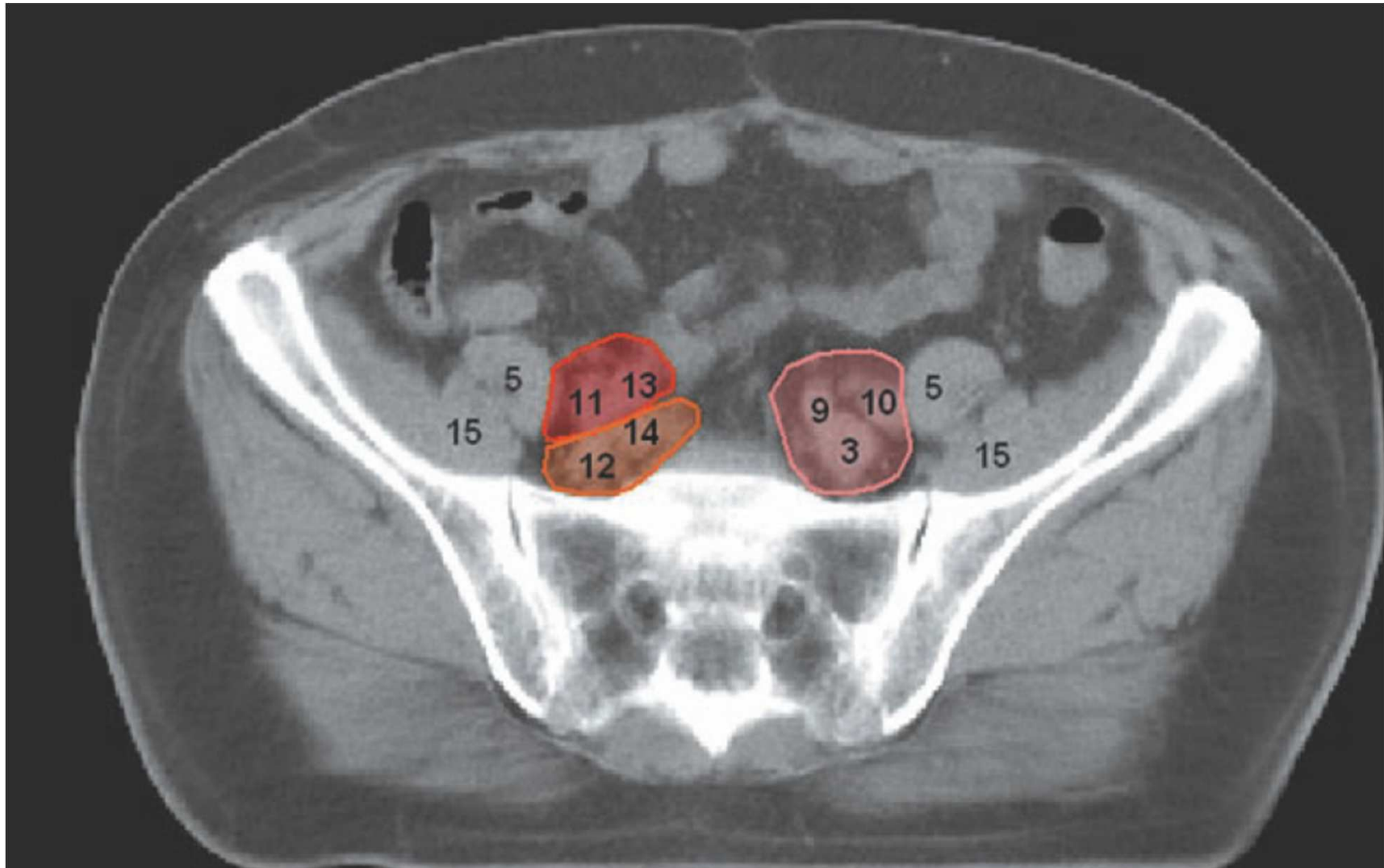
Anorectal Cancer



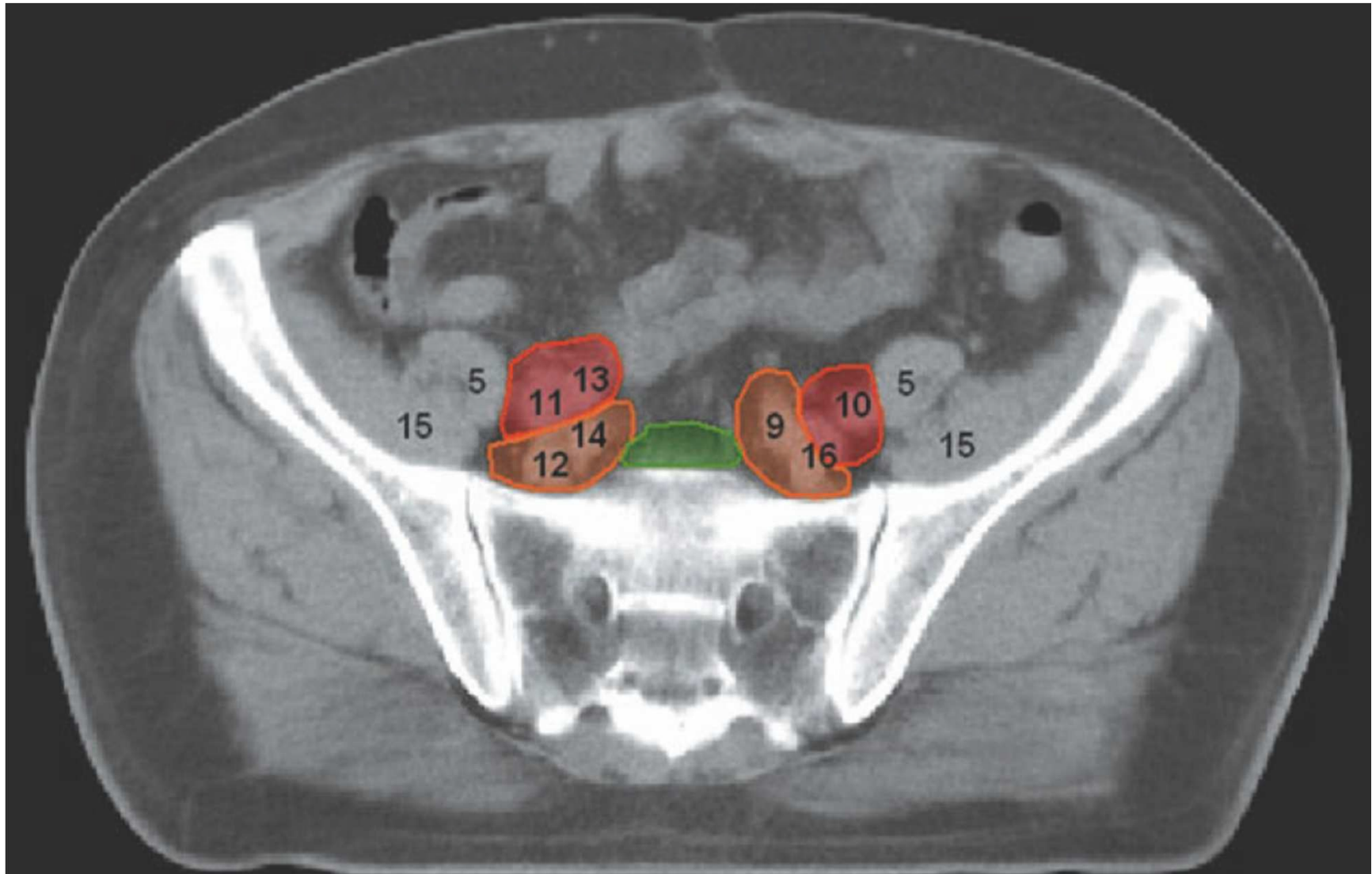
Pelvic & Inguinal lymph nodes



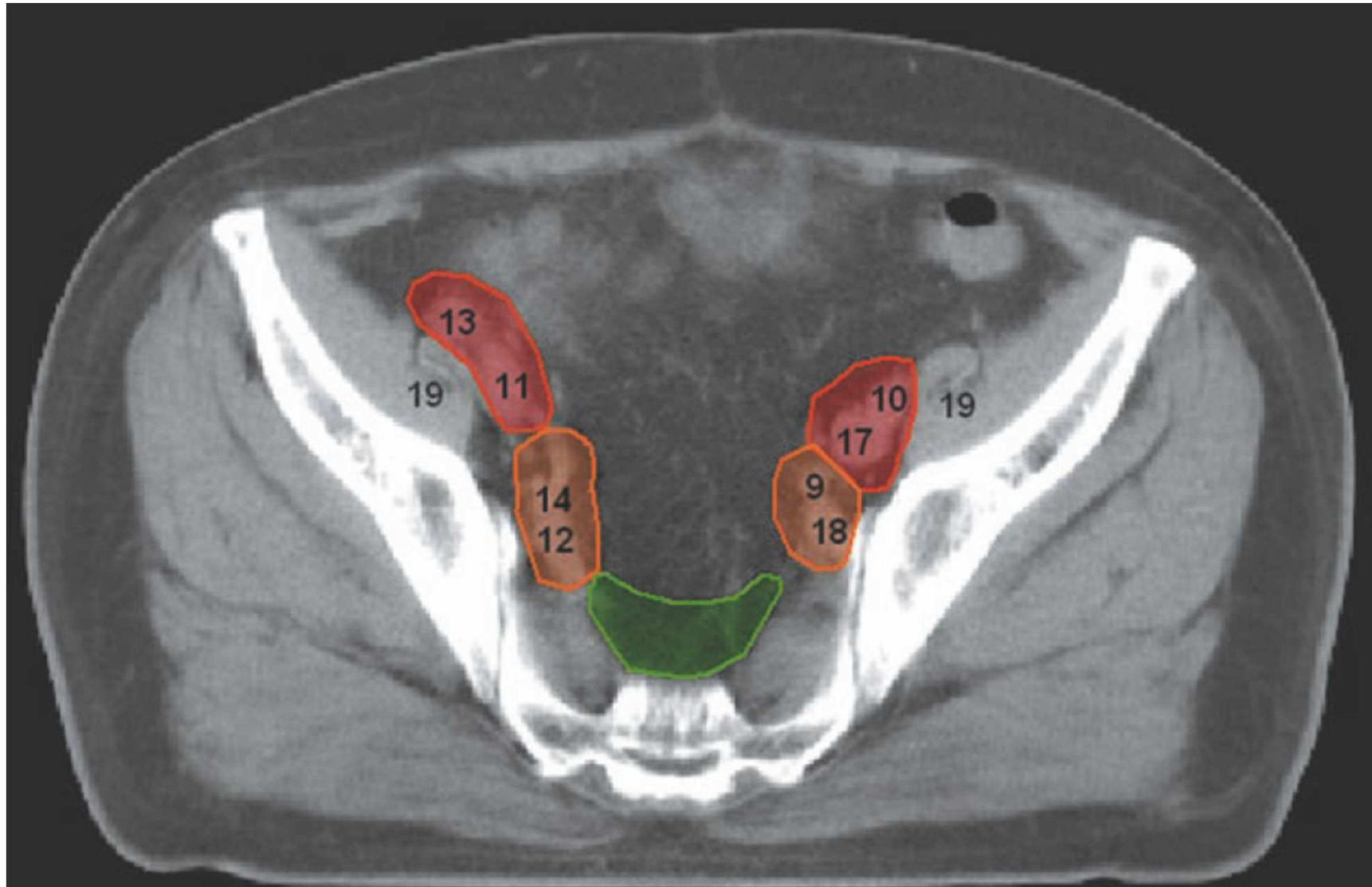
Pelvic & Inguinal lymph nodes



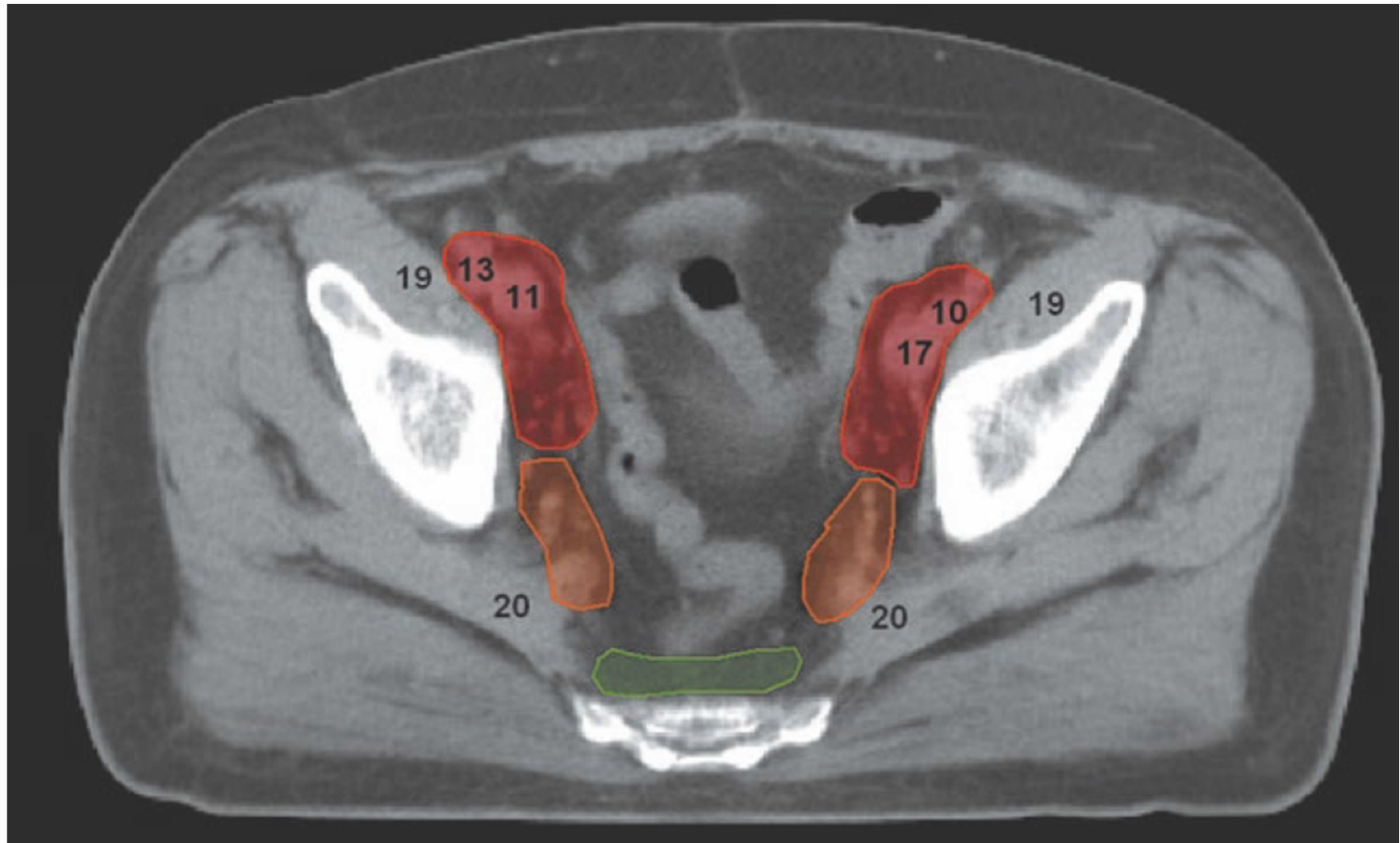
Pelvic & Inguinal lymph nodes



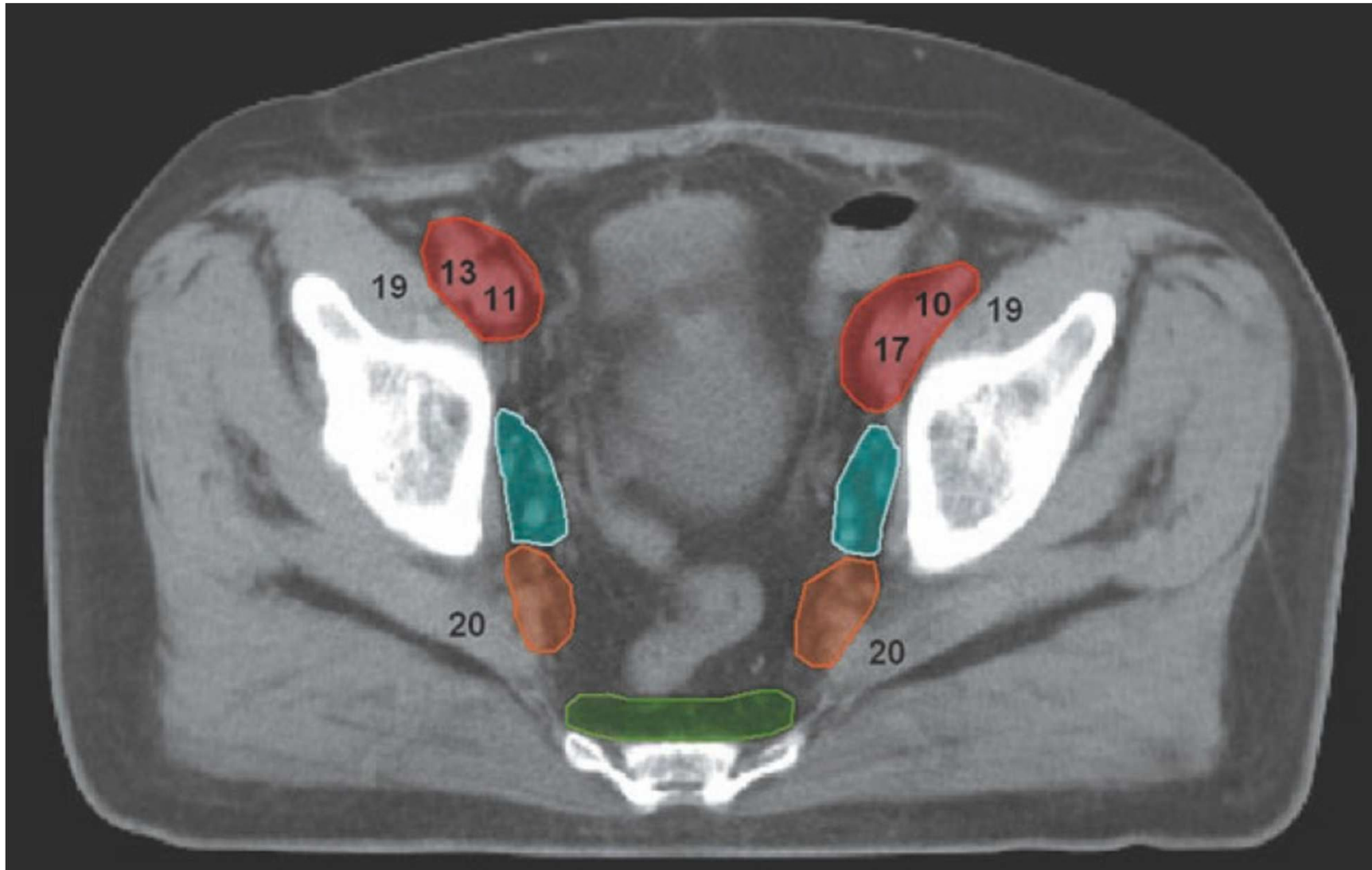
Pelvic & Inguinal lymph nodes



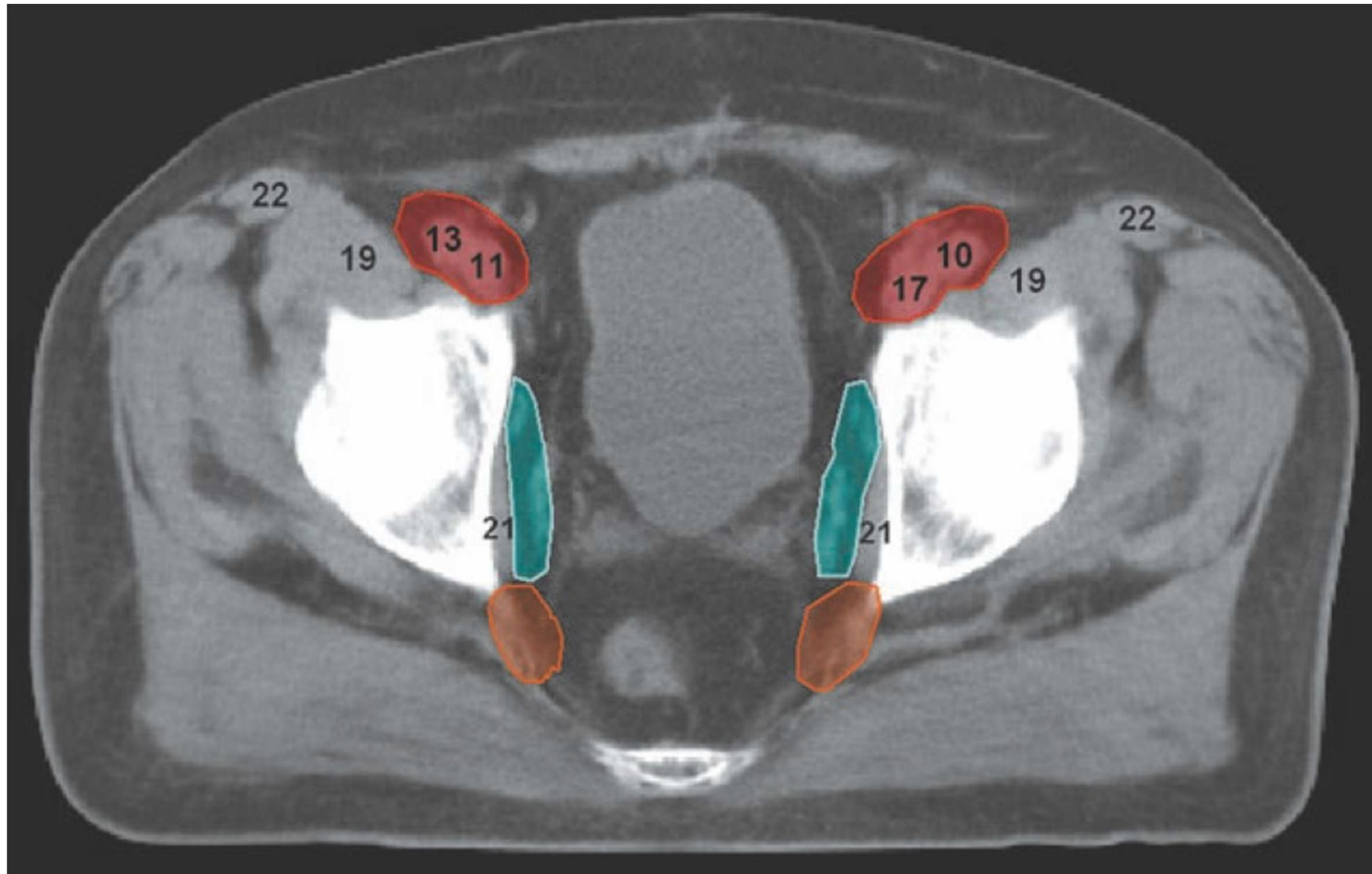
Pelvic & Inguinal lymph nodes



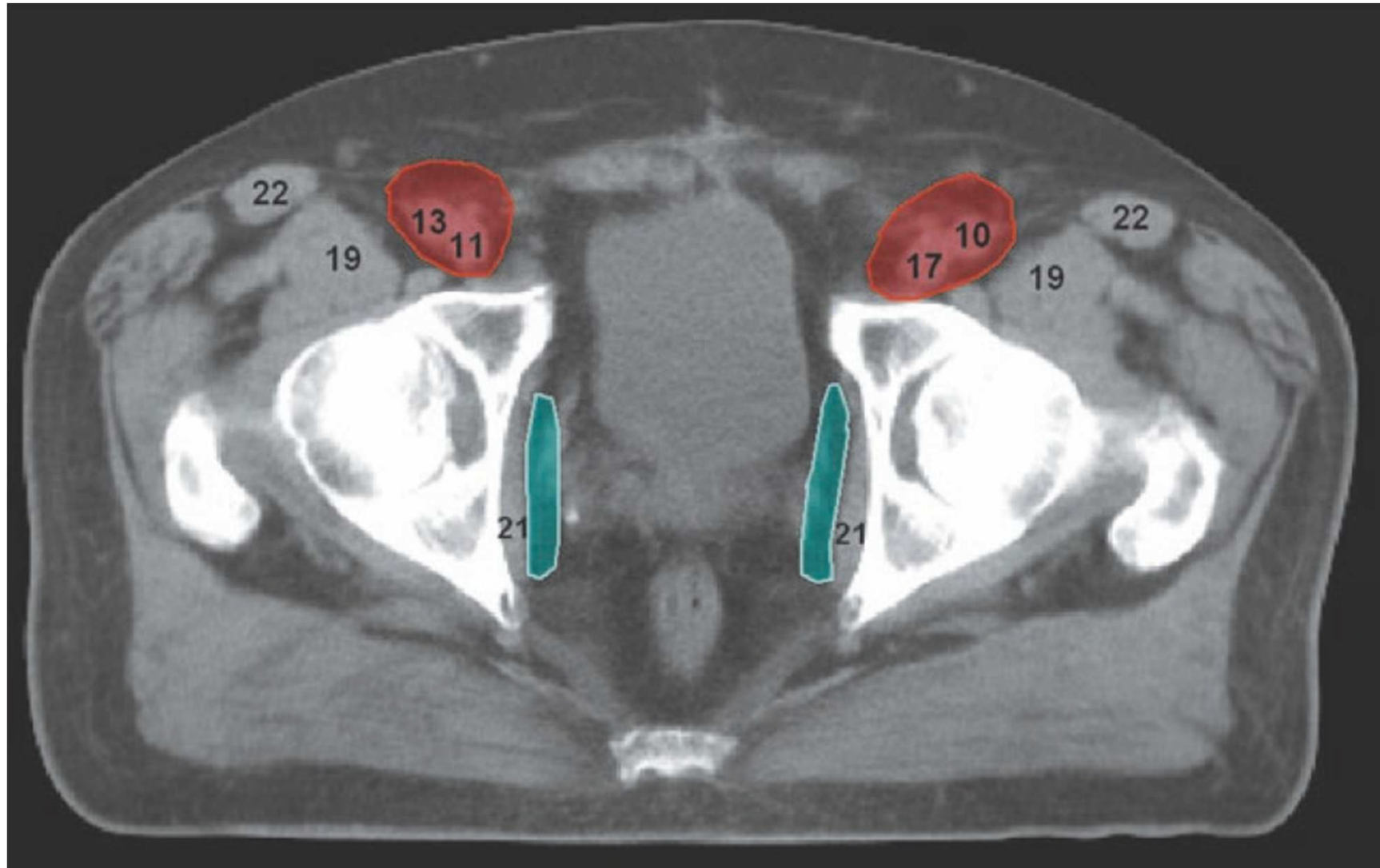
Pelvic & Inguinal lymph nodes



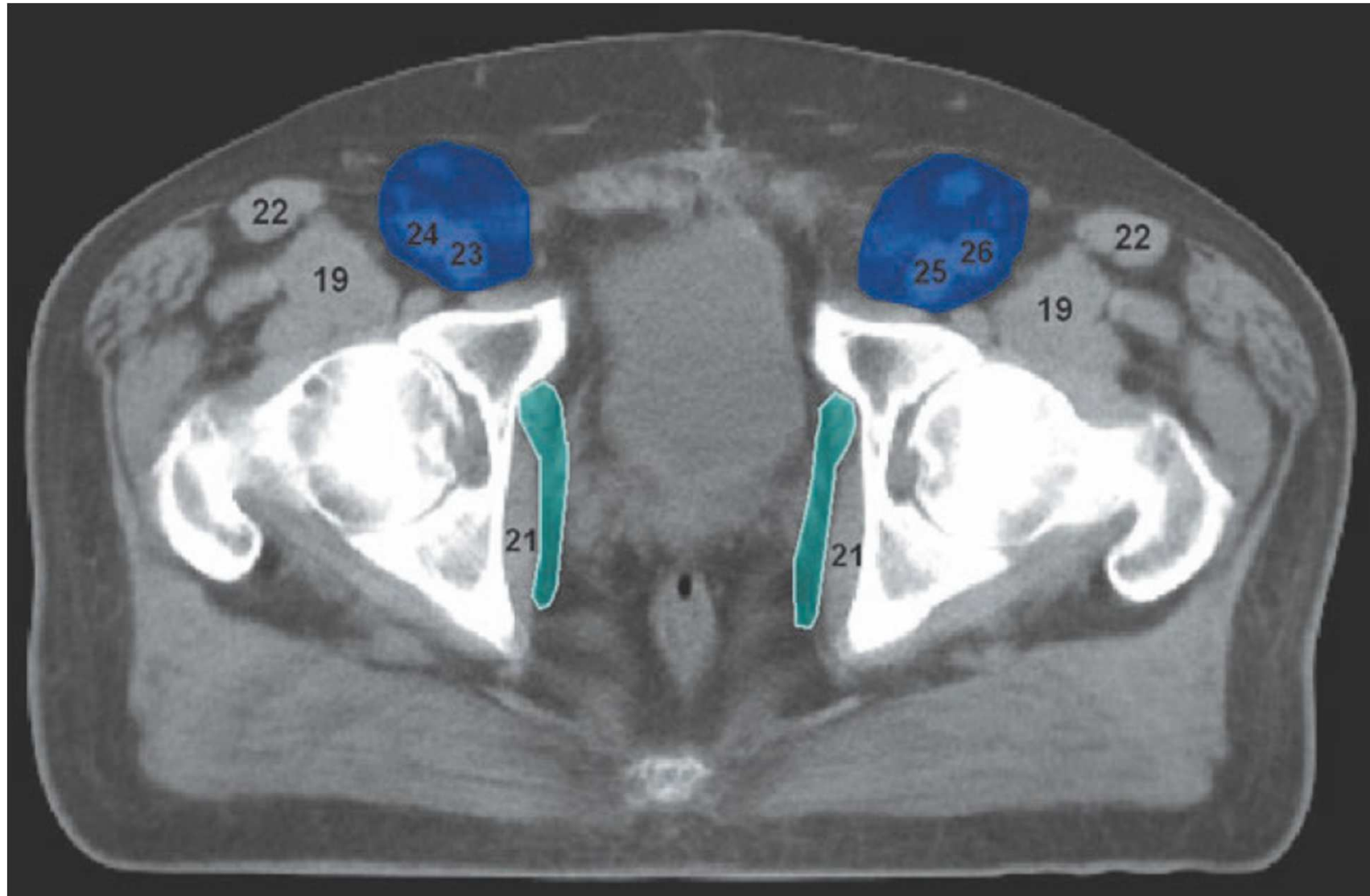
Pelvic & Inguinal lymph nodes



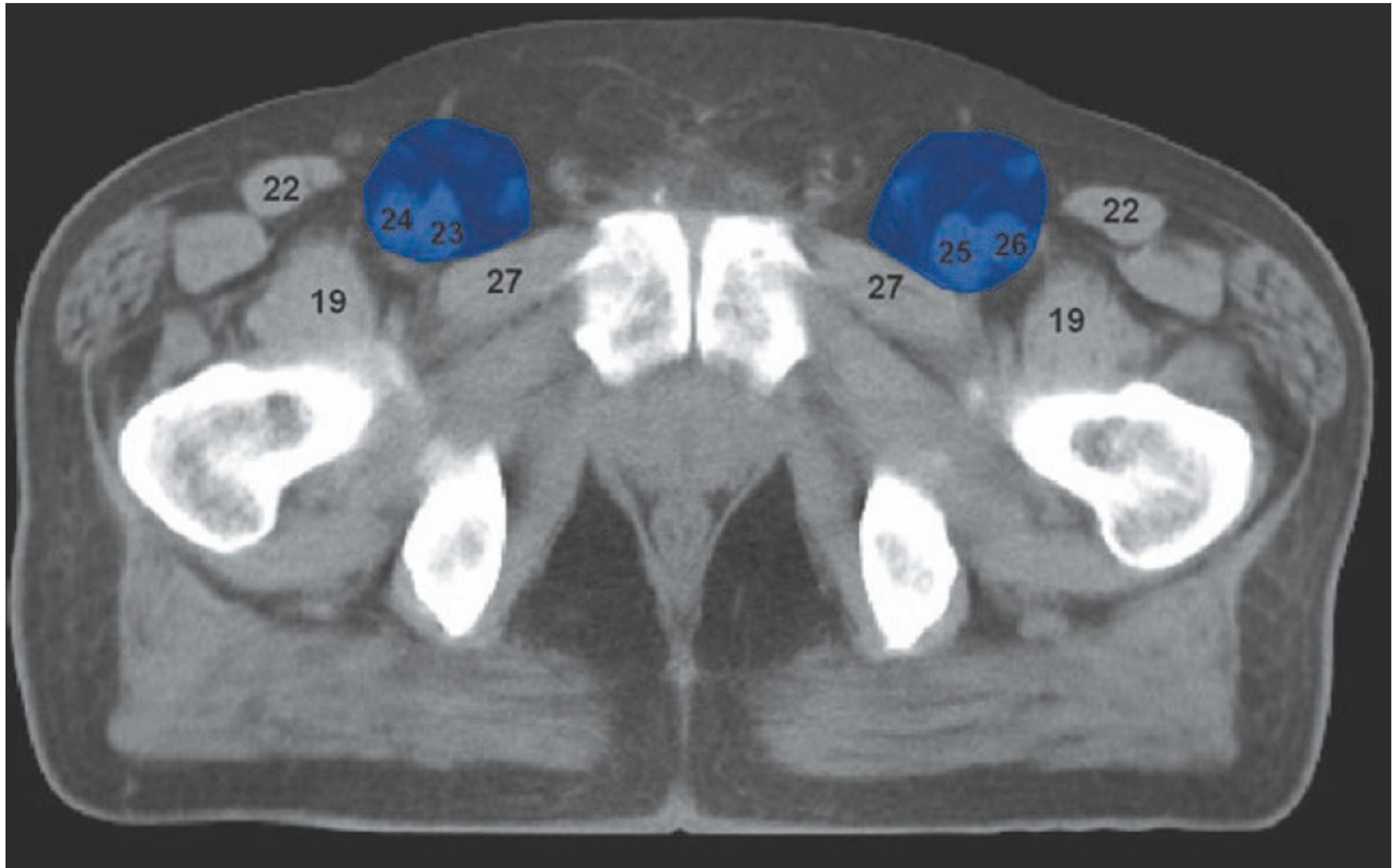
Pelvic & Inguinal lymph nodes



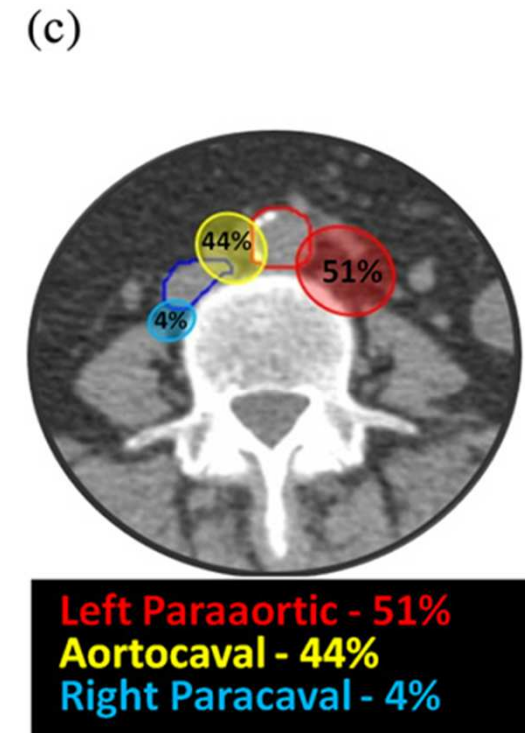
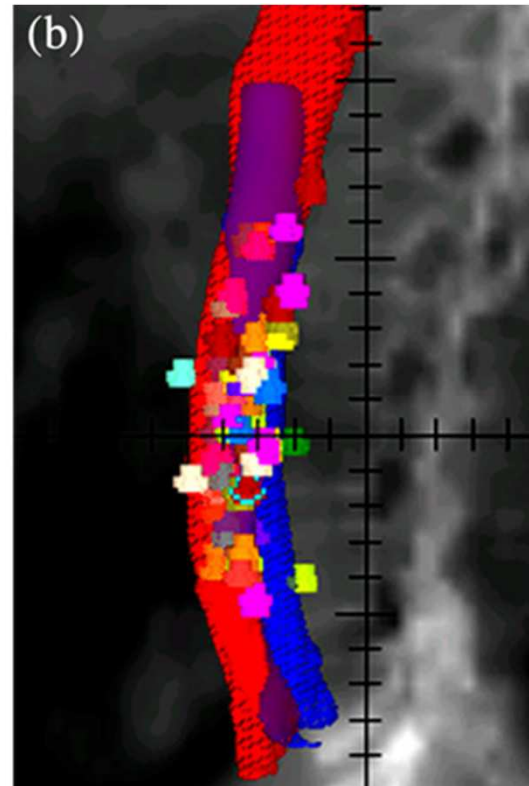
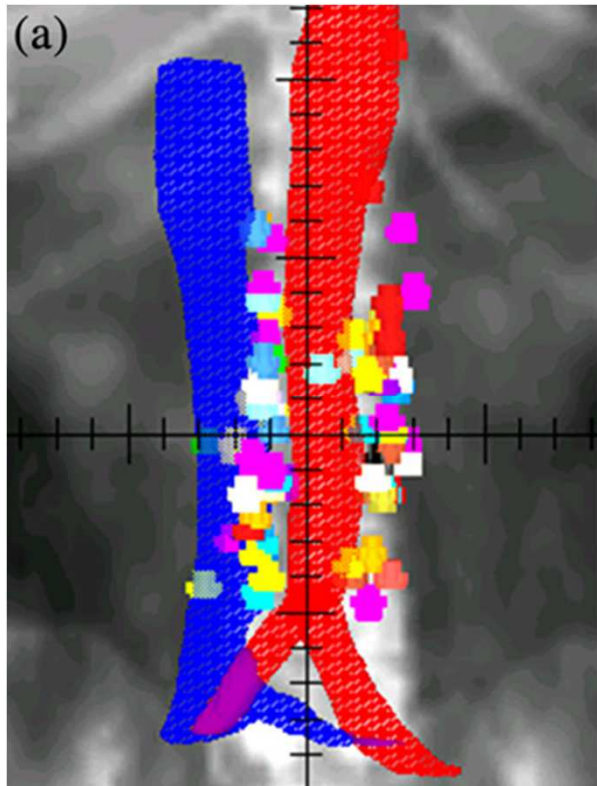
Pelvic & Inguinal lymph nodes



Pelvic & Inguinal lymph nodes



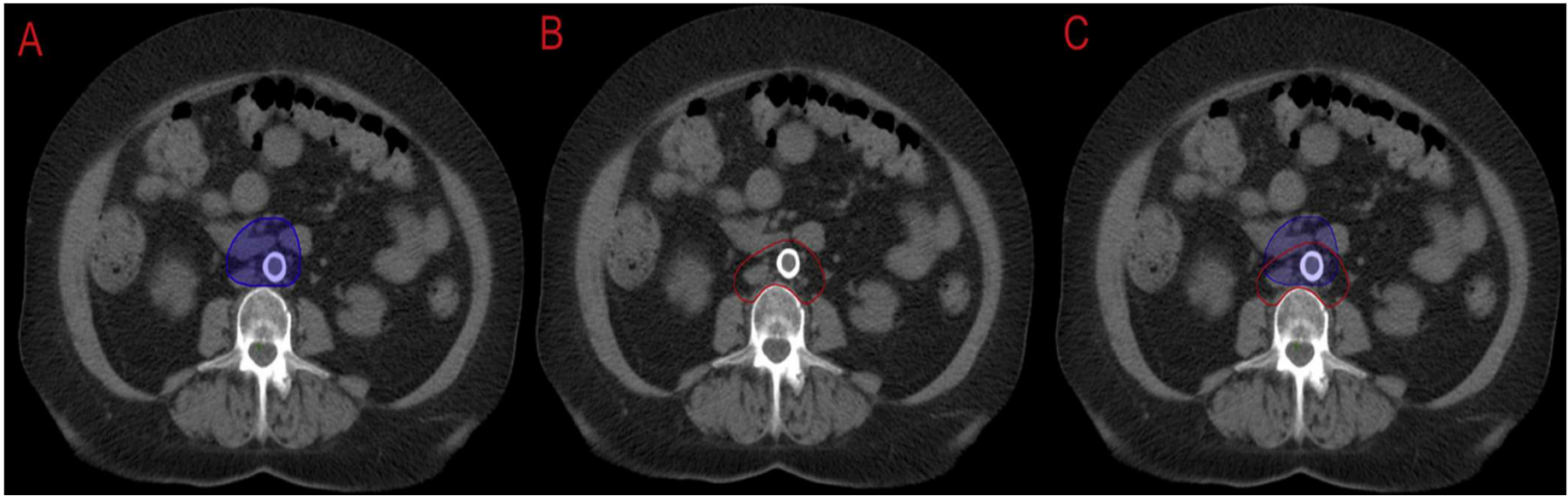
Paraaortic nodes



Paraaortic nodes

- ❑ Nodal contouring of the PA region should not be defined by a fixed symmetrical or asymmetrical circumferential margin around the vessels.
- ❑ The space between the aorta and psoas and between the IVC and aorta should be covered adequately because these are common locations of PA lymph nodes
- ❑ Anatomic boundaries to cover the center of >95% of positive PA lymph nodes are the following:
 - ❑ Laterally, the medial border of left and right iliopsoas muscles;
 - ❑ Posteriorly, the anterior border of the vertebral body;
 - ❑ Anteriorly, at least a 0.75-cm margin in soft tissue around vessels

Paraaortic nodes



For microscopic disease superiorly, contouring should extend to renal vessels, and for patients who have highest nodal involvement at renal vessels, one can consider including retrocrural nodes.

Pelvic & Inguinal lymph nodes



- ❑ Therefore, the major vessels alone do not provide sufficient surrogate information for lymph node CTV definition, and it is necessary to incorporate bony & other landmarks
- ❑ The current evolution toward the use of high-precision IMRT to treat pelvic lymph nodes at risk of harboring occult disease demands accurate knowledge of the location of these nodes for target-volume definition



THANK YOU